

CLINICAL STUDY

The role of laparoscopic Heller myotomy in the treatment of achalasia

Zonca P^{1,2}, Cambal M^{2,3}, Labas P³, Hrbaty B³, Jacobi CA²*Department of Surgery, University and University Hospital Ostrava, Czech Republic. pavel.zonca@fno.cz***Abstract:** *Aim:* To evaluate the results of laparoscopic Heller myotomy in our group of patients.*Method:* A retrospective clinical trial was carried out to evaluate the indication, technique and controversies of laparoscopic Heller myotomy in the achalasia treatment. The following symptoms were evaluated prior and after Heller myotomy: dysphagia, heartburn, nausea/vomiting after meal and asthma/coughing. The patients were evaluated by the use of Likert score. Statistical analysis was performed by using Student t test. The intra-operative (operation time, intraoperative complications, blood loss, conversion rate), and peri-operative parameters (morbidity, mortality, hospital stay) were evaluated as well. The patients who underwent laparoscopic Heller myotomy were included in the trial. All patients were perioperatively managed by a multidisciplinary team. *Results:* The evaluation of fourteen patients was performed (average age: 53.2 yrs., eleven men, two women, BMI 23.6 kg/m²). The patients were indicated for surgery in all of the stages (I–III). Previous semiconservative therapeutic modalities were performed in thirteen patients. The standard laparoscopic technique for Heller myotomy with semifundoplication was applied. All the observed symptoms were statistically improved after the surgery ($p=0.05$). The average operating time was 89 minutes. Intraoperative blood loss was below 20 ml. There was no conversion to open surgery. An average hospital stay was 4.3 days. Morbidity was 14.3 % and mortality 0 %. In one patient esophageal mucosa perforation was intra-operatively identified and sutured. Post-operative course in this patient was without any complications.*Conclusion:* The laparoscopic Heller myotomy has become the “gold standard” procedure for achalasia. It is an excellent method allowing precise operation technique with good visualization of the esophagogastric junction. The operation with this approach is safe, efficient, and with excellent reproducible operative results. The correct and early indication for surgery is crucial. The delayed diagnosis with a late indication for surgery is not an exemption (*Tab. 2, Fig. 2, Ref. 36*). Text in PDF www.elis.sk.

Key words: Heller, myotomy, achalasia.

Idiopathic achalasia is a severe neuromuscular disorder of the esophagus. Sir Thomas Willis described this entity in 1674 (1). Primary idiopathic achalasia is a very rare condition with the incidence of 1:100,000 per year (2). It is usually diagnosed in patients between 25 and 60 years. The distribution in men and women is proportional. Despite its low incidence this disorder has been very well documented and understood. Its typical features are loss of peristalsis or incoordination of peristalsis in the tubular esophagus. Another feature is the inability of the lower esophageal sphincter (LES) to reach a proper post-deglutitive relaxation. A wide spectrum from absence of optimal relaxation to hypertonus of LES could be identified by manometry (3). The cause of idiopathic achalasia is a degeneration of nervous cells in plexus myentericus. Especially the cells causing relaxation of LES and distal esophagus are damaged. The etiology of this damage is still elusive (4). The

leading clinical symptom of achalasia is dysphagia. According to literature it occurs in up to 100 % (5). Weight loss, regurgitation, recurrent bronchopulmonary infection, chest pain, hiccups, and cough are other clinical symptoms. Belching reflex is altered (6). Incidence of heartburn is 72 %. Although heartburn is a cardinal symptom of gastroesophageal reflux, the sensation of heartburn in patients with achalasia is explained by the retention of acidic or noxious contents in esophagus or by lactate production from bacterial fermentation within the esophagus (7, 8). Achalasia is considered as an important precancerous condition. The incidence of esophageal cancer is assumed to be between 4–6 % of patients with achalasia (9). Primary achalasia occurs two hundred times more often in patients with Down syndrome compared with the normal population (10). The existence of genetic inheritance because of familial cases is suggested (11). Infection and autoimmune etiology are considered to be other reasons for achalasia (12). Secondary achalasia or pseudoachalasia are caused by narrowing of distal esophagus. The most often case of pseudoachalasia is esophageal and cardia cancers (13). Another reason is benign strictures. Rare entities such as dysphagia lusoria should be mentioned as well. Imaging studies, esophagogastroduodenoscopy, and manometry represent the basic necessary diagnostic tools for the diagnosis and for therapeutic strategy. High-resolution manometry and multichannel intraluminal

¹Department of Surgery, University and University Hospital Ostrava, Czech Republic, ²Center for Visceral and Minimally Invasive Surgery, Wesseling, Germany, and ³1st Department of Surgery, Faculty of Medicine, Comenius University, Bratislava, Slovakia

Address for correspondence: P. Zonca, MD, PhD, Department of Surgery, University and University Hospital Ostrava, 17. listopadu 1790, CZ-708 52 Ostrava-Poruba, Czech Republic.

nal impedance monitoring represent newer techniques. Esophageal endosonography and thoracic/abdominal CT is a routine part of pre-operative diagnostic to exclude secondary achalasia as well.

Method

A retrospective clinical trial was carried out to evaluate the indication, technique and controversies of laparoscopic Heller myotomy in the achalasia treatment. The following symptoms were evaluated prior and after Heller myotomy: dysphagia, heartburn, nausea/vomiting after meals and asthma/coughing. Patients were evaluated using Likert score (0–10 scale). The follow-up data was obtained one year after the surgery. Statistical analysis was performed by using Student t test. Patients who underwent laparoscopic Heller myotomy for achalasia were included in the trial. Esophageal manometry, esophagogastrosopy, esophagogram, and thoracic/abdominal CT were performed before the surgery.

There were no special exclusive criteria in this trial. The intra-operative (time of operation, intraoperative complications, blood loss, conversion rate) and peri-operative parameters (morbidity, mortality, hospital stay) were evaluated as well. The pre-operative diagnostic, management before surgery and peri-operative management were a result of the multidisciplinary team care.

Surgical technique and postoperative management

The standard technique for Heller myotomy was used. Supine position with abducted lower extremities was used. The trocar placement was the same in the antireflux surgery. The five-port technique was used. The position of all ports is shown in the scheme (Fig. 1). One 10-mm, one 12-mm and three 5-mm ports were used. The 10-mm port was placed in the middle line approximately one third above umbilicus in the xiphoido-umbilical line under direct visualization. A 12-mm port was placed with visual guidance along the left anterior axillary line at the subcostal margin. A 5-mm port was placed contralaterally in the same position. Liver retractor was inserted through this port. One 5-mm port was placed between 10-mm and 12-mm ports. Finally, a 5-mm port was

placed in the epigastric area. 12-mm capnoperitoneum was used. The 30-degree optic inserted through the 10-mm port was used. Dissection of pars flaccidum omenti minoris was the first step. The gastrohepatic ligament and the phrenoesophageal membrane were opened by using the hook with diathermy. Both crura were identified and the phrenoesophageal membrane was opened. The exposure of esophagus was achieved. Preparation of fundus with dissection of vasa gastrica brevia followed. We prefer posterior dissection of esophagus not only in patients having non-anatomical position of gastroesophageal junction with hiatal hernia, but in all patients as well. The vagal nerves were identified and preserved. High preparation of thoracic esophagus was performed. The blunt division of the longitudinal muscle fibers of the esophagus with the dissector was performed. It should be about 1–2 cm above gastroesophageal junction. The dissection with the hook followed after the proper layer had been reached. It was a very important moment. The operation field should be absolutely clear to avoid an injury of esophageal mucosa. Cranial myotomy should be about 6–8 cm long. Myotomy should be caudally extended by 3 cm from the gastroesophageal junction on the ventral wall of the stomach. The complete division of the sling fibers should be reached. Concomitant esophagogastrosopy was used to guide the myotomy. It helps to avoid an inadequate myotomy and a possible perforation. Perforation is easily identifiable by using endoscopy with an air test. Insufflation through the endoscope was performed while the myotomized segment was under irrigant. Semifundoplication according to Dor was a standard part after myotomy in our patients. It helped to secure the myotomized segment and prevented gastro-esophageal reflux after myotomy. The easy-flow drainage was inserted. The ports were removed under a visual control. The wounds were closed. Esophagogram was performed on the first post-operative day. The aim was to evaluate the emptying of esophagus after myotomy and to check its leakage. If the leakage test was negative and the esophagus emptied swiftly, a liquid diet was initiated. The liquid diet followed for the next 4 weeks. The patients were seen in the out-patient-clinic one week after the surgery. Further follow-ups were done in cooperation with a family doctor and a gastroenterologist as well.

Results

We performed an evaluation of fourteen patients with one follow-up (average age: 53.2 yrs., eleven men, two women, BMI 23.6 kg/m²). The indication for surgery was a result of our multidisciplinary team. The patients were indicated for surgery in all of the stages (I–III) (Fig. 2). Three patients were in stage I, six patients were in stage II, and five patients were in stage III. The duration of symptoms before myotomy was 6.7 years on average. The primary indication for surgery was done only in one patient. In thirteen patients primary pneumatic dilatation and/or Botox injection was undertaken in parallel to various medicamentous treatments. The standard laparoscopic technique for Heller myotomy with semifundoplication according to Dor was applied. The evaluation of dysphagia by using Likert score prior and after surgery was 8.9±4.1 (mean, SD) and 2.1±1.9 respec-

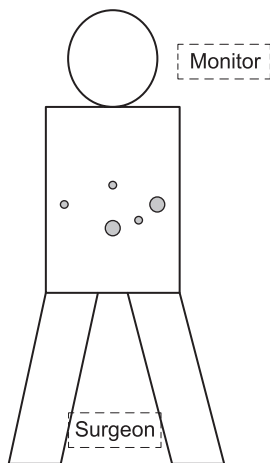


Fig. 1. Position of ports.

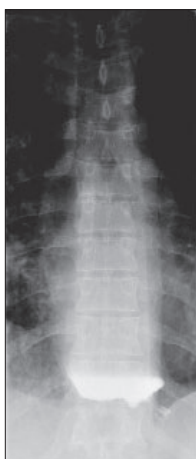

Fig. 2. Esophagogram – Achalasia gr. III.

tively. Ten patients (71.4 %) reported infrequent or no dysphagia. The values of heartburn score, nausea/vomiting after meal, and asthma/coughing prior and after surgery follow: 4.3 ± 2.2 , 2.4 ± 1.6 (heartburn), 5.4 ± 3.1 , 1.3 ± 1.2 (nausea/vomiting), 5.7 ± 3.1 , 1.2 ± 1.0 (asthma/coughing). These results are summarized in Table 1. All the observed symptoms were statistically improved after surgery (Student t-test, $p=0.05$).

The average operating time was 89 minutes. The intraoperative blood loss was below 20 ml. There was no conversion to open surgery. The mean hospital stay was 4.3 days. Morbidity was 28.6 % and mortality 0 %. Esophageal mucosa perforation was intraoperatively identified and sutured in one patient. Post-operative course in this patient was without any other complications. Other complications are summarized in Table 2.

No patient underwent adjuvant pneumatic dilation or surgery within the one-year follow-up. Thirteen (92.8 %) patients reported their satisfaction with the procedure.

Discussion

The main problem in achalasia treatment is that the etiology of achalasia remains still unknown. The restoration of esophageal

Tab. 1. Observed symptoms: dysphagia, heartburn, nausea/vomiting after meal, asthma/coughing.

	Pre-operative score	Post-operative score
Dysphagia	8.9 ± 4.1	2.1 ± 1.9
Heartburn	4.3 ± 2.2	2.4 ± 1.6
Nausea/vomiting after meal	5.4 ± 3.1	1.3 ± 1.2
Asthma/coughing	5.7 ± 3.1	1.2 ± 1.0

Tab. 2. Complications.

Intraoperative complications	
Intraoperative mucosa perforation	1
Postoperative complications	
Postoperative leak	0
Urinary retention	1
Pneumothorax	1
Pneumonia	1

peristalsis and lower esophageal sphincter relaxation in physiological sense is not available at the present time. This is the reason why the treatment is not causal and remains in palliative range. There are some possibilities of pharmacological treatment, chemical denervation, pneumatic dilatation, or surgical myotomy. The aim of palliative therapy is to open or to destroy lower esophageal sphincter to facilitate the esophageal transit. A radical option for terminal stage with irreversible progression is esophagectomy. Techniques for the treatment of megaesophagus in patients who underwent myotomy like cardioplasty and Roux-en-Y partial gastrectomy (Serra-Dória procedure) have been described.

The primary diagnostic procedures are performed usually by nonsurgeons. Myotomy is considered to be an invasive procedure. It is the reason why many patients go to surgery secondarily after a conservative and repeatedly unsuccessful semiconservative treatment. In our cohort the majority of patients (92.8 %) indicated for myotomy after the previous semiconservative therapy. Achalasia is diagnosed on average five years after the onset of the first diagnosed symptoms. In our cohort it was 6.7 years. It represents a second problem, because the treatment starts in the advanced and more complicated stages of disease (14). Considering the above mentioned fact of the late indication for surgery after semiconservative treatment and the late diagnosis the patients go to surgery with a significant delay.

Achalasia is a rare illness. Only few randomized controlled clinical trials have been performed with the aim to show the best treatment strategy. Cardiomyotomy was originally described by Ernst Heller in 1913. He originally used anterior and posterior myotomies (15). The Dutch surgeon Zaaijer described an anterior cardiomyotomy with the aim to decrease the excessive gastroesophageal reflux after anterior and posterior myotomies (16). In the nineties minimal invasive surgery brought other possibilities with laparoscopic approach or video-assisted thoracoscopic surgery. The thoracoscopic approach is applied in case of the simultaneous presence of an epiphrenic diverticulum, or concurrent diffuse esophageal spasm in order to perform a long thoracic myotomy (17).

Until the nineties of the 20th century endoscopic dilatation was considered to be a first-line therapy (18).

It was confirmed, that recurrence after pneumatic dilatation was experienced by approximately 40 % of patients (19, 20). Zaninotto compared patients treated with Botox injections and with laparoscopic Heller myotomy and fundoplication. 66 % of the patients in Botox group had recurrence. In the laparoscopic Heller myotomy group the recurrence was 13.5 % (21).

Thanks to the minimal invasive myotomy this technique became a first line therapy. Endoscopic methods should be reserved for patients who are poor surgical candidates (22).

The debate about the appropriate initial management continues despite the superior data of surgical approach. The discussion about the possible negative influence of the previous semiconservative treatment on the outcome of the surgical therapy goes on. Some authors emphasize the fact that patients initially treated preoperatively with Botox injection had a more difficult laparo-

scopic Heller myotomy. A correlation between the difficulty and preoperative pneumatic dilatation was not confirmed in this trial (23). Cowgill confirmed no correlation between degrees of fibrosis in the esophageal muscle with preoperative endoscopic therapy and concluded that the preoperative endoscopic therapy before laparoscopic Heller myotomy did not determine the difficulty of the operation or long-term outcomes (24). There are more trials with different results.

Many questions have arisen regarding the outcomes after laparoscopic Heller myotomy. The following should be taken into consideration: the frequency and severity of gastroesophageal reflux, the need for an antireflux fundoplication, the need for intraoperative endoscopy, the extent of myotomy, the need for robotics, and others.

The procedure facilitating transit without pathological gastroesophageal reflux is optimal. Most authors recommend to combine the myotomy with fundoplication. Myotomy without antireflux procedure is rare. The advantages of partial or complete fundoplication were debated as well. Gockel suggested that complete fundoplication is rare because of the risk of persistent postoperative hypertension of the sphincter. 180° anterior Dor semifundoplication might be important because of covering the occult mucosal perforation. The dorsal 270° fundoplication could keep apart the edges of muscles after myotomy (25). The fundoplication should not be too tight. Di Martino compared Dor laparoscopic semifundoplication and calibrated Nissen-Rossetti fundoplication with the achieved similar results (26). The anterior semifundoplication was recommended according to Richard trial (27). The patients in our cohort received Dor semifundoplication.

The length of cranial myotomy should be 6–7 cm and caudally 1.5–2 cm. The incomplete division of muscle fibers is another reason for recurrence (28). Craft recommended the length of myotomy approximately 10 cm up the esophagus and 4 cm down in the anterior gastric wall (29). Wright confirmed the efficacy of myotomy above 3 cm on to the stomach in terms of reducing persistent dysphagia (30). The direction of the myotomy over the stomach is debated as well. Scar formation, short myotomy or remnant muscle fibers are the most cited causes of recurrence after myotomy. Gockel mentioned the possibility of addition posterior myotomy to the scheduled anterior myotomy.

The complication rate after pneumatic dilatation and surgical myotomy is very important. Many reviews show the incidence of mucosa lesion about 4 %. The lethality after myotomy is about 0.5 % (31). The perforation rate after pneumatic dilatation is about 1 % per dilatation session and lethality below 0.5 % (32). The results of meta-analysis would suggest that pneumatic dilatation is the more effective endoscopic treatment in the long term (greater than six months) for patients with achalasia (33).

Gockel presented an interesting trial regarding persistent and recurrent achalasia after Heller myotomy. She identified two groups of patients with therapeutic failure. The first group had an early recurrence after technical failure of myotomy or a scarring process. It is important to follow the standardized operation technique to avoid this type of recurrence. The second group had a late recurrence with irreversible progression of the disease. These patients

developed megaesophagus. An analysis of potential predictors for the operation results would be interesting. A bigger cohort of patients would enable such analysis.

New techniques are being developed. The recent experimental studies in mice suggest that transplantation of neuronal stem cells might be a future therapeutic option. Neuronal stem cells injected in the pylorus survived and even expressed nitric oxide synthase (34). Pasricha reported a method of submucosal endoscopic myotomy with no skin incision in an experimental model (35). The long-term results of techniques like oral endoscopic myotomy have not been available. A similar situation exists in the stent introduction in achalasia treatment.

Thanks to the genes diagnostics it will be possible to early identify some cases with achalasia in the future. They are several risky genes for achalasia. The Achalasia Risk Consortium has been founded to help to identify these risky genes and to make the gene therapy possible in the future (www.achalasia-konsortium.de) (36).

Conclusion

The precise history helps to identify the disease in its early stage. The correct and early indication for surgery is crucial. Laparoscopic Heller myotomy has been established as a first-line therapy for severe achalasia including old fit patients. An operation with this approach is safe, efficient, and with excellent reproducible operative results. Patient's preference should be included in the decision-making process. It can be considered as a secondary treatment if the patient does not respond to less invasive modalities. In the future other techniques could be developed. Further studies are needed to investigate the role of immunosuppressive therapies when an autoimmune etiology is suspected.

References

1. Gockel HR, Schumacher J, Gockel I, Lang H, Haaf T, Nothen MM. Achalasia: will genetic studies provide insights? *Hum Genet* 2010; 128: 353–364.
2. Vela MF, Vaezi MF. Cost-assessment of alternative management strategies for achalasia. *Expert Opin Pharmacother* 2003; 4: 2019–2025.
3. Spechler SJ, Castell DO. Classification of oesophageal motility abnormalities. *Gut* 2001; 49: 145–151.
4. Park W, Vaezi MF. Etiology and pathogenesis of achalasia: the current understanding. *Am J Gastroenterol* 2005; 100: 1404–1414.
5. Howard PJ, Maher I, Pryde , Cameron EW, Heading RC. Five years prospective study of the incidence, clinical features, and diagnosis of achalasia in Edinburgh. *Gut* 1992; 33: 1011–1013.
6. Masey BT, Hogan WJ, Dodds WJ, Dantas RO. Alteration of the upper esophageal sphincter belch reflex in patients with achalasia. *Gastroenterology* 1992; 103: 1574–1579.
7. Smart HI, Foster PN, Evans DF, Slevin B, Atkinson M. Twenty four hour oesophageal acidity in achalasia before and after pneumatic dilatation. *Gut* 1987; 28: 883–887.
8. Eckardt AJ, Eckardt VF. Current clinical approach to achalasia. *WJG* 2009; 28 (32): 3969–3975.

9. **Steitz JM, Ellis FH, Gibb SP, Heatley GM.** Achalasia and squamous cell carcinoma of the esophagus: analysis of 241 patients. *Ann Thorac Surg* 1995; 59: 1604–1649.
10. **Zarate N, Mearin F, Gil-Vernet JM, Camarasa F, Malagelada JR.** Achalasia and Down's syndrome: coincidental association or something else? *Am J Gastroenterol* 1999; 94: 1674–1677.
11. **Annese V, Napolitano G, Minervini MM, Perri F, Ciavarella G, Di Giorgio G, Andriulli A.** Family occurrence of achalasia. *J Clin Gastroenterol* 1995; 20: 329–330.
12. **Moses PL, Ellis LM, Anees MR, Ho W, Rothstein RI, Meddings JB, Sharkey KA, Mawe GM.** Antineuronal antibodies in idiopathic achalasia and gastro-oesophageal reflux disease. *Gut* 2003; 52: 629–636.
13. **Carter M, Deckman RC, Smith RC, Burrell MI, Traube M.** Differentiation of achalasia from pseudoachalasia by computed tomography. *Am J Gastroenterol* 1997; 92: 624–628.
14. **Eckardt VF.** Clinical presentations and complications of achalasia. *Gastrointest Endosc Clin N Am* 2001; 11: 281–292.
15. **Heller E.** Extramuköse Kardioplastik beim chronischen Kardiospasmus mit Dilatation des Oesophagus. *Mitt Grenzgeb Med Chir* 1914; 27: 141–149.
16. **Zaaijer JH.** Cardiospasm in the aged. *Ann Surg* 1923; 77: 615–617.
17. **Gockel I, Sgourakis G, Drescher DG, Lang H.** Impact of minimally invasive surgery in the spectrum of current achalasia treatment options. *Scand J Surg* 2011; 100: 72–77.
18. **Bennett JR, Hendrix TR.** Treatment of achalasia with pneumatic dilatation. *Mod Treat* 1970; 7: 1217–1228.
19. **Farhoomand K, Connor JT, Richter JE, Achkar E, Vaezi MF.** Predictors of outcome of pneumatic dilation in achalasia. *Clin Gastroenterol Hepatol* 2004; 2: 389–394.
20. **Karamanolis G, Sgouros S, Karatzias G.** Long-term outcome of pneumatic dilation in the treatment of achalasia. *Am J Gastroenterol* 2005; 100: 270–274.
21. **Zaninotto G, Vergadoro V, Annese V et al.** Botulinum toxin injection versus laparoscopic myotomy for the treatment of esophageal achalasia: economic analysis of a randomized trial *Surg Endosc* 2004; 18: 691–695.
22. **Roll GR, Rabl C, Ciovica R, Peeva S, Campos GM.** A Controversy That Has Been Tough to Swallow: Is the Treatment of Achalasia Now Digested? *J Gastrointest Surg* 2010; S33–S45.
23. **Horgan S, Hudda K, Eubanks T, McAllister J, Pellegrini CA.** Does botulinum toxin injection make esophagomyotomy a more difficult operation? *Surg Endosc* 1999; 13: 576–579.
24. **Cowgill SM, Villadolid DV, Al-Saadi S, Ropsemurgy AS.** Difficult myotomy is not determined by preoperative therapy and does not impact outcome. *JLS* 2007; 11: 336–343.
25. **Gockel I, Sgourakis G, Drescher DG, Lang H.** Impact of minimally invasive surgery in the spectrum of current achalasia treatment options. *Scand J Surg* 2011; 100: 72–77.
26. **Di Martino N, Brillantino A, Moncaco L, Marano L, Schettino M, Porfidia R, Izzo G, Cosenza A.** Laparoscopic calibrated total vs partial fundoplication following Heller myotomy for oesophageal achalasia. *World J Gastroenterol* 2011; 17 (29): 3431–3440.
27. **Richards WO, Torquati A, Holzman MD et al.** Heller myotomy versus Heller myotomy with Dor fundoplication for achalasia: a prospective randomized double-blind clinical trial. *Ann Surg* 2004; 240: 405–415.
28. **Ellis FH Jr.** Failure after esophagomyotomy for esophageal motor disorders: causes, prevention, and management. *Chest Surg Clin N Am* 1997; 7 (3): 477–488.
29. **Craft RO, Aguilar BE, Flahive C, Merritt M, Chapital AB, Schlinkert RT, Harold KL.** Outcomes of minimally invasive myotomy for the treatment of achalasia in the elderly. *JLS* 2010; 14: 342–347.
30. **Wright AS, Williams CW, Pellegrini CA, Oelschlager BK.** Long term outcomes confirm the superior efficacy of extended Heller myotomy with Toupet fundoplication for achalasia. *Surg Endosc* 2007; 21: 713–718.
31. **Hunter JG, Smith CD, Branum GD, Waring JP, Trus TL, Cornwell M, Galloway K.** Laparoscopic fundoplication failures: Patterns of Failure and Response to Fundoplication Revision. *Ann Surg* 1999; 230: 595–604.
32. **Vaezi MF, Richter JE, Wilcox CM, Schroeder PL, Birgisson S, Slaughter RL, Koehler RE, Baker ME.** Botulinum toxin versus pneumatic dilatation in the treatment of achalasia: a randomised trial. *Gut* 1999; 44 (2): 231–239.
33. **Leyden JE, Moss AC, MacMathuna P.** Endoscopic pneumatic dilatation versus botulinum toxin injection in the management of primary achalasia. *Cochrane Database Syst Rev* 2006; (4): CD005046.
34. **Urbach DR, Hansen PD, Khajanchee YS et al.** A decision analysis of the optimal initial approach to achalasia: Laparoscopic Heller myotomy with partial fundoplication, thoracoscopic Heller myotomy, pneumatic dilatation, or botulinum toxin injection. *J Gastrointest Surg* 2001; 5: 192–205.
35. **Pasricha PJ, Hawari R, Ahmed I et al.** Submucosal endoscopic esophageal myotomy: A novel experimental approach for the treatment of achalasia. *Endoscopy* 2007; 39: 761–764.
36. **Gockel I, Muller M, Schumacher J.** Achalasia – a disease of unknown cause that is often diagnosed too late. *Dtsch Arztebl Int* 2012; 109 (12): 209–214.

Received May 14, 2012.

Accepted October 27, 2013.