

## EXPERIMENTAL STUDY

# Gastroprotective effects of CoQ<sub>10</sub> on ethanol-induced acute gastric lesions

Karakaya K<sup>1</sup>, Barut F<sup>2</sup>, Hanci V<sup>4</sup>, Can M<sup>3</sup>, Comert M<sup>1</sup>, Ucan HB<sup>1</sup>, Cakmak GK<sup>1</sup>, Irkorucu O<sup>1</sup>, Tascilar O<sup>1</sup>, Emre AU<sup>1</sup>

Department of General Surgery, Zonguldak Karaelmas University, Medical Faculty, Zonguldak, Turkey.  
vhanci@gmail.com

**Abstract:** *Introduction:* Alcohol consumption is frequently associated with gastric mucosal lesions. The purpose of this study was to determine the effect of Coenzyme-Q<sub>10</sub> (CoQ<sub>10</sub>) supplementation on the ethanol-induced gastric mucosal damage in a rat model.

*Material and method:* Sixty-four female wistar albino rats were randomly divided into 8 groups (n = 8). Studies were performed in ethanol induced gastric ulcer model in Wistar albino rats. Famotidine at a dose of 5 mg/kg or 20 mg/kg and CoQ<sub>10</sub> at a single dose of 10 mg/kg or 20 mg/kg and 30 mg/kg for 7 days were administered as pretreatment. All the rats in study groups received 2 ml/kg ethanol 95 % intragastrically, 30 minutes after pretreatment. Four hour after ethanol administration, all rats were sacrificed and their stomachs were removed under ketamin anaesthesia. Gastric protection was evaluated by measuring the ulcer index, MDA concentrations, and histopathological studies.

*Results and discussion:* Rats pretreated either with famotidine or CoQ<sub>10</sub> had significantly diminished gastric mucosal damage which was assessed with gross and microscopic analysis (p < 0.00625). MDA levels were significantly lower in famotidine 20 mg/kg and CoQ<sub>10</sub> pretreatment for 7 days group (p < 0.00625).

*Conclusion:* CoQ<sub>10</sub> affords gastroprotection against ethanol-induced gastric mucosal lesions in rats especially after repetitive administrations (Tab. 3, Fig. 2, Ref. 35). Text in PDF [www.elis.sk](http://www.elis.sk).

Key words: gastric ulceration, ethanol, Coenzyme-Q<sub>10</sub>, rats.

Coenzyme Q (CoQ), a 1,4 benzoquinone with a 50 carbon isoprenoid side chain, is an essential cofactor in the adenosine triphosphate generation via mitochondrial oxidative phosphorylation (1). In addition, CoQ plays a role in inhibiting lipid peroxidation (2). Various CoQ homologues exist, containing different numbers of isoprenoid units in the side chain. CoQ<sub>9</sub> and CoQ<sub>10</sub> are present in human plasma and both are equally efficient as antioxidants and redox carriers (3). CoQ<sub>10</sub>, the dominant form, is lipophilic and transported in the lipoprotein particles in circulation (4). CoQ is synthesized in the body, and is also obtained from the diet, particularly by meat products (5). Commercially available CoQ<sub>10</sub> preparations have been marketed for years. The reduced form of CoQ<sub>10</sub> is the only endogenously synthesized lipophilic antioxidant that serves to protect biological membranes against oxidation (6).

The balance between aggressive and defensive factors determines the occurrence of gastric injury and the development of peptic ulcer. The invention of proton-pump inhibitors in anti-ulcer

therapy had revolutionized treatment of peptic ulcers; nevertheless, the definitive cure for this disease process has not been established currently. Accordingly, the identification of novel therapeutic agents with acceptable safety profiles, cost-effectivity and tolerable side effects are required.

Various experimental animal models have been performed to evaluate the gastro protective effects of different substances in literature (7–9). Non steroid anti-inflammatory agent and ethanol induced gastric injury models are two of the most preferred methods (10, 11).

The aim of the present study was to evaluate the effects of CoQ<sub>10</sub> supplementation on ethanol-induced gastric mucosal injury in an experimental setting. The determination of gastroprotective action of the agent might shed some valuable light on the prevention and treatment of peptic ulcer disease.

## Study design

The surgical procedure, use of anesthesia, and animal care methods in the experiments were consistent with the guidelines in the National Institute of Health's Guide for the Care and Use of Laboratory Animals (National Institutes of Health publication No. 86–23, revised 1985, Bethesda, MD) and were approved by the School of Medicine Ethics Committee of the Zonguldak Karaelmas University. The study was carried out on 64 female Wistar albino rats weighing 300–400 g. The rats were housed in a temperature controlled room (22–24 °C) and illumination (12:12 h light/dark-

<sup>1</sup>Department of General Surgery, Zonguldak Karaelmas University, Medical Faculty, Zonguldak, Turkey, <sup>2</sup>Department of Pathology, Zonguldak Karaelmas University, Medical Faculty, Zonguldak, Turkey, <sup>3</sup>Department of Biochemistry, Zonguldak Karaelmas University, Medical Faculty, Zonguldak, Turkey, and <sup>4</sup>Dokuz Eylul University, Department of Anesthesiology, Izmir, Turkey

**Address for correspondence:** V. Hanci, MD, Department of Anesthesiology, Dokuz Eylul University, 35340 Izmir, Turkey.  
Phone: +90.530.6433240

ness). All animals were fed with pellet food produced especially for experimental animals. Water was available ad libitum.

The experimental procedures were carried out in accordance with international guidelines for the use and care of laboratory animals. The drugs used in this experimental study (CoQ-10; Solgar Vit. & Herb, Leonia, NJ, USA, and Famoser, Biofarama İlaç San. Tic AŞ., Istanbul, Turkey) were purchased. The oral formulation of famotidine was dissolved in distilled water. CoQ<sub>10</sub> was dissolved in soybean oil. All drug solutions and suspensions were freshly prepared. All experiments were performed during the same time of the day to avoid diurnal variations of putative regulators of gastric functions. Gastric ulcers were inflicted by oral administration of ethanol 95 % at a dose of 2 ml/kg after 17 h starvation from 17 pm to 10 am.

The animals were allocated randomly into eight groups. Gastric lesions were induced using a model modified from Mizui et al and Birdane et al (11, 12). In Group 1 (saline; n = 8) rats received 2 ml/kg of saline by gavage. Rats in Group 2 (ethanol, n = 8) received 2 ml/kg ethanol 95 %. The rats in group 3 (vehicle, n = 8) received 2 ml/kg soybean oil by gavage. The rats in group 4 (Famotidine 5, n = 8) and group 5 (Famotidine 20, n = 8) were pretreated with famotidine 5 mg/kg and 20 mg/kg, respectively. Rats in groups 6 (CoQ<sub>10</sub> 10, n = 8) and group 7 (CoQ<sub>10</sub> 20, n = 8) were pretreated with 10 mg/kg and 20 mg/kg CoQ<sub>10</sub> dissolved in soybean oil, respectively. The rats in group 8 (CoQ<sub>10</sub> 7x30, n = 8) received CoQ<sub>10</sub> for 7 days at a dose of 30 mg/kg/d by gavage. Rats pretreated with vehicle, famotidine or CoQ<sub>10</sub> at different doses were given 2 ml/kg ethanol 95 %, 30 minutes after pretreatment. All the animals completed the study protocol. Four hours after oral administration of ethanol all of the groups were anesthetized with intramuscular injection of 100 mg/kg Ketamin (Ketalar, Parke Davis-Eczacıbaşı, Istanbul, Turkey). A midline abdominal incision was performed. All of the rats were sacrificed via cardiac puncture, and immediate gastrectomy was performed. Subsequently, each stomach was incised along the greater curvature and rinsed in ice-cold distilled water, after which it was pinned out on a wax platform. Macroscopic damage to the gastric mucosa was assessed. Hemorrhagic and ulcerative lesions were counted and their lengths measured on square millimeter paper. Gastric mucosal lesions were expressed as the sum of the lengths (mm) of all lesions for each stomach and it was used as the Ulcer Index (UI) (7, 13, 14). Gastric lesions were evaluated by two independent researchers blinded to the study protocol. Mean score of the two independent observers were taken into account, and the sum of the total scores was divided by the number of animals to obtain the mean UI for each group.

The stomach of each animal was divided into two equal parts for histopathologic and biochemical analysis. One part of the stomach was excised and immersed in saline and was immediately stored at -40 °C for measurement of malondialdehyde (MDA) levels. The other part of stomach was fixed in 10 % neutral formalin.

#### Biochemical analysis

Gastric tissues were homogenized in ten volumes of 150 mM ice-cold KCl using a glass teflon homogenizer (Ultra Turrax IKA T18 Basic) after cutting the tissues into small pieces with scissors

(for 2 min at 5000 rpm). The homogenate was then centrifuged at 5000×g for 15 min. The supernatant was used for analysis. High performance liquid chromatographic analysis was performed with isocratic method using a Shimadzu HPLC system (Kyoto, Japan) using a commercial MDA kit (Immundiagnostik AG, Bensheim, Germany). The first step in determining MDA is a sample preparation with derivatization reagent transforms MDA into a fluorescent product. Afterwards, the pH was optimized and reaction mixture (20 ml) was then on a reversed phase C18 column (18.5 mm, 125x4 mm) at 30°C. The flow rate was 0.8 ml/min. Fluorimetric detection was performed with excitation at 515 nm and emission at 553 nm. The detection limit was 0.15 mmol/L and linearity was up to 100 mmol/L. Total protein in the extracts and supernatants was determined by the method of Fujita et al (15) on Advia 2400 autoanalyser (Siemens, Tarrytown, NY, USA). Results were expressed nmol/g protein for MDA.

#### Histopathological analysis

The samples for histology were dehydrated and embedded in paraffin and cut into 5 µm sections. The sections were stained with hematoxylin and eosin (H&E) and examined under the light microscope for histological changes by a blinded pathologist. Histological evaluation was performed on the glandular stomach of animals. Gastric mucosal injury was assessed semi-quantitatively using the previously described histopathological changes such as ulceration, hemorrhage, focal necrosis, mucosal congestion, glandular cell degeneration, inflammation, and edema. Microscopic scoring of the tissue samples was performed on a scale ranging from 0 to 3 (0: None, 1: Mild, 2: Moderate, 3: Severe) (16, 17). Histopathological score for each group was determined as the sum of the scores for each parameter (Tab. 1).

#### Power analysis

Sample size estimation was based on the standard deviation in a similar study performed by Arun et al (17). To use the Ulcer Index (7.70 ± 0.54) determined by Arun et al (17) from their previous study of ethanol induced gastric ulcer on rats, ( in order to detect a 5 % change in ulcer index, with an alpha error of 0.05 and a power of 80 %), calculated sample size should be at least 8 rats per group.

#### Statistical analysis

The statistical analysis was performed using Statistical Package for the Social Sciences (SPSS) version 12.0 for Windows.

**Tab. 1. Histopathological evaluation of groups.**

Group	n	Histopathologic Score
Sham	8	0*
Ethanol	8	15.38±4.10 †
Soybean -Oil	8	8.62±2.06
Famotidine 5	8	8.50±1.51
Famotidine20	8	2.87±1.72
CoQ <sub>10</sub> 10	8	7.12±2.85
CoQ <sub>10</sub> 20	8	9.12±3.39
CoQ <sub>10</sub> 7x30	8	3.62±1.84

\* p < 0.00625 compared to the all other groups, except Famotidine 20 group and CoQ<sub>10</sub> 7x30, † p < 0.00625 compared to the all other groups

**Tab. 2. Macroscopic evaluation of gastric mucosa.**

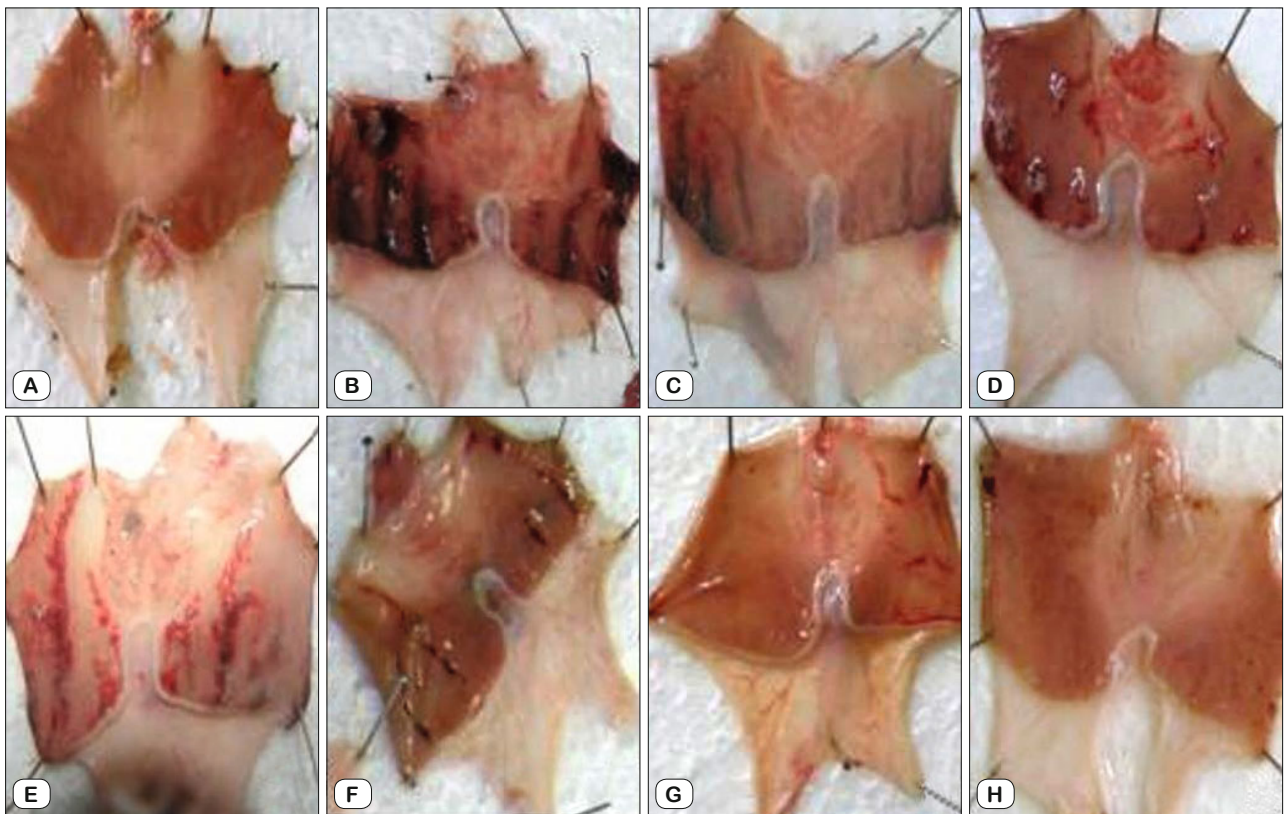
Groups	n	Weight (g)	Ulcer Index (mm <sup>2</sup> )
Sham	8	340.75±27.31	0 *
Ethanol	8	348.12±15.27	102.44±16.33
Soybean -Oil	8	346.62±17.47	67.12±21.40
Famotidine 5	8	343.38±26.68	71.25±26.55
Famotidine20	8	329.50±32.90	5.68±4.23 †
CoQ <sub>10</sub> 10	8	345.62±30.91	56.87±31.33 †
CoQ <sub>10</sub> 20	8	327.38±21.71	70.00±28.40
CoQ <sub>10</sub> 7x30	8	332.88±21.37	15.00±9.63 †

The values are presented as Mean ± SD, \*p < 0.00625 compared to the all other groups, † p < 0.00625 compared to the Group Ethanol

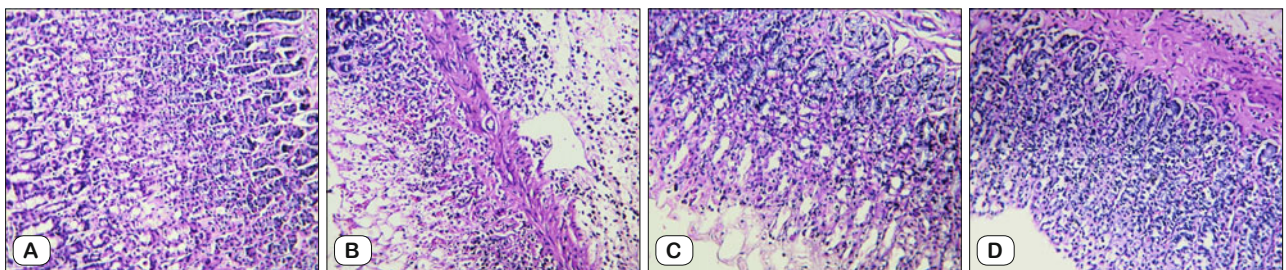
**Tab. 3. MDA contents of gastric tissues.**

Groups	N	MDA (nmol/g protein)
Sham	8	0.72±0.24 *
Ethanol	8	2.67±0.76 †
Soybean -Oil	8	1.56±0.25
Famotidine 5	8	1.51±0.22
Famotidine20	8	1.07±0.22
CoQ <sub>10</sub> 10	8	1.41±0.16
CoQ <sub>10</sub> 20	8	1.55±0.23
CoQ <sub>10</sub> 7x30	8	1.06±0.22

\* p < 0.00625 compared to the all other groups except Famotidine 20 group and CoQ<sub>10</sub> 7x30, † p < 0.00625 compared to the all other groups



**Fig. 1. Gross appearances of the opened stomachs in the experimental groups. A – Normal mucosa in saline group, B – Severe mucosal injury in ethanol group, C – Mucosal injury in vehicle group, D – Mucosal lesions in group famotidine 5 mg/kg, E, F – Appearances of the gastric mucosa in groups pretreated with CoQ<sub>10</sub> 10 mg/kg, and 20 mg/kg respectively, Protected gastric mucosa in Group CoQ<sub>10</sub> 7x30 mg/kg (G), and in Group Famotidine 20 mg/kg (H).**



**Fig. 2. The histopathologic appearances of gastric mucosa in different experimental groups. A – Normal gastric mucosa in sham group, B – Ulceration in gastric mucosa in ethanol group C – Focal necrosis in gastric mucosa in famotidine 5 mg/kg treatment group, D – Gastric mucosa resembling normal appearance in CoQ<sub>10</sub> 7x30 mg treatment group (A, B, C, D – H&E, x200).**

All data are expressed as mean  $\pm$  SD. Mann Whitney U test with Bonferroni correction were used for statistical analysis of data in all groups. Our study consists of 8 groups, after Mann–Whitney U test with Bonferroni correction,  $p < 0.00625$  was considered as statistically significant.

## Results

The acute gastric lesions were induced by the intragastric administration of 2 ml/kg of 95 % ethanol. There was no statistically significant difference in mean body weights between groups. Macroscopic analysis demonstrated ethanol (2 ml/kg) induced ulcer formation in all stomachs except sham group. Gastric mucosal damage was found to be reduced by famotidine and CoQ<sub>10</sub> pretreatment, dependent of the dose administered. Famotidine 20 mg/kg and CoQ<sub>10</sub> administered for a week at a dose of 30 mg/kg has revealed most potent gastroprotective effect against ethanol induced gastric mucosal damage when compared to sham group ( $p = 1$  and  $p = 0.1$ , respectively).

Soybean oil administration as a vehicle of CoQ<sub>10</sub> has reduced gastric damage. In vehicle group, the mean count of ulcerations and the UI were both determined to be lower than the ethanol group. In vehicle group diminished UI were observed, however, it reached no significance ( $p > 0.00625$ ). Macroscopic evaluations of the gastric damage are presented in Table 2.

In damaged stomachs, mucosal lesions with different size and forms were dispersed to all stomach surfaces. Those lesions consisted of elongated bands parallel to the long axis of the stomach. The interobserver variations for ulcer count and ulcer area were found to be 3.1 %, and 4.6 %, respectively. Lesions of the gastric mucosa in each group are shown in Figure 1.

MDA, a quantitative marker of lipid peroxidation, was measured in the gastric tissues. MDA levels were found to be higher in ethanol group than in the other groups. There were significant differences between ethanol and the other groups in respect to tissue MDA levels ( $p < 0.00625$ ). MDA levels for each group are shown in Table 3.

Ethanol group had the highest histopathological score of gastric mucosal damage, and famotidine 20 mg/kg and CoQ<sub>10</sub> 7x30 mg/kg groups achieved the lowest histopathological score. Soybean oil and single dose of CoQ<sub>10</sub> administration have partial gastroprotective effect proved in histopathological evaluation. Details of the histopathological evaluations are shown in Table 1. Microscopic views of the normal and damaged gastric mucosa are shown in Figure 2.

## Discussion

Ethanol-induced gastric ulcers have been widely used for the evaluation of gastroprotective activity of several compounds. In experimental ethanol induced gastric injury models different volumes of ethanol in different concentrations had been applied. Some authors administered absolute ethanol, whereas the others administered ethanol in lower concentrations up to 40 % (9, 11, 17–22). In the present study, the administration of 95 % ethanol

with a dose of 2 ml/kg by gavage was selected to induce gastric injury. Alcohol related gastric injury in humans is mostly a result of chronic exposure at a lower concentration. Nevertheless, gastroprotective effects of various compounds are mostly examined in experimental rat models with a single dose of ethanol administration. Accordingly, single dose of ethanol was selected for the present study. Long term administration of ethanol is another option to be studied, as performed by Li et al (23). Ethanol induced gastric injury models possess various limitations, including the differences between the doses and concentrations of ethanol that is preferred by authors. Consequently, the results gathered from the single dose ethanol induced gastric injury models need to be correlated with the chronic administration, before being reflected to human subjects. The authors of the present study preferred to administer ethanol in a high concentration, but in low-median volumes used in the literature (17–22).

The pathogenesis of ethanol-induced gastric ulcer production in animals is multifactorial, involving superficial aggressive cellular necrosis as well as the release of superoxide anion and hydroperoxy free radicals by the metabolism of ethanol in the body (24). These mediators decrease gastric microvascular blood flow, triggering a series of events that lead to gastric tissue damage (25). Besides prostaglandins, L-Arginine /nitric oxide (NO) pathway is a major protective system in gastric mucosa via relaxation of the arterial smooth muscles. Vasodilatation is important in the maintenance of gastric integrity, by means of blood flow enhancement, preventing the activation of inflammatory factors and removing irritants (26). Ethanol, on the other hand, alters the gastric mucosal barrier by its disorganizing effects on gastric surfactants (27).

Historically, there were many products of natural sources with gastroprotective properties. The gastroprotective effect of CoQ<sub>10</sub> and soybean oil, as a vehicle, was examined in this experimental rat study. Dairy foods have gastroprotective effects against stress induced gastric damage in rat. Dietary fats reduce secretion of gastric juice mediated by GIP (28). Commercially available oil preparations contain CoQ either dominantly in CoQ<sub>9</sub> or CoQ<sub>10</sub> (29). Lipid compounds also act as a surfactant and maintain surface hydrophobicity, which is reduced by ulcerogenic agents (30). Those properties of lipid compounds protect gastric mucosa against harmful effects of ethanol. We observed that soybean oil has partial gastroprotective effect against ethanol induced gastric damage itself. Gastroprotective effect of soy-bean oil (vehicle) was found similar to the single dose of CoQ<sub>10</sub> administration. It was significantly lower than that of repetitive administration of CoQ<sub>10</sub>. Zhang et al (29) found out that the oil itself did not make any significant difference in hepatic CoQ concentrations in their experimental study. They also showed that total CoQ concentration of the liver was time (administration period) dependent. Interestingly, administration of CoQ<sub>10</sub> did not suppress endogenous CoQ<sub>9</sub> synthesis. Even with as little as 0.3  $\mu$ mol CoQ<sub>10</sub>/100g body weight for 4 days was found to be sufficient for doubled tissue CoQ<sub>10</sub> concentration (29). Although, Zhipeng et al reported that, CoQ<sub>10</sub> was well tolerated by rats at higher doses, literature lacks any other study determining CoQ concentration in gastric tissues in an experimental gastric ulcer model (31). Consequently, the

determination of CoQ levels in gastric tissues should be evaluated in further studies of ulcer models. Gastroprotective effects of soybean and single dose of CoQ<sub>10</sub> are not potent. It is stated that it is impossible to achieve sufficient tissue concentration with a single dose of CoQ administration. Accordingly, repetitive and successive doses of CoQ administration lead to an increase in tissue concentration which in turn over expresses the protective effect of CoQ (30). Consistent with the literature, upon treatments of rats in group 8 for 7 days with CoQ<sub>10</sub> dissolved in soybean oil, we observed significant gastro-protection. CoQ<sub>10</sub> was administered for 7 days in higher doses to get at least 100 % increase in tissue CoQ concentration. Gastroprotective effect in group 8 pretreated with 30 mg/kg CoQ<sub>10</sub> for 7 days shows the affect of repetitive CoQ<sub>10</sub> administration. The lack of animal group pretreated with a single dose of 30 mg/kg BW CoQ<sub>10</sub> is a short arm of this study. Our present study reveals that repeated doses of exogenous CoQ<sub>10</sub> administration provide significant gastroprotection in an experimental model of gastric injury induced by ethanol administration.

CoQ<sub>10</sub> has been shown to correlate positively with body mass index (32). All the rat groups in our study were comparable with the other groups in respect to mean body weights.

It's a well-known fact that CoQ plays several crucial roles in the body, acting as an essential antioxidant, influencing the stability of membranes, and acting as a redox electron carrier in the mitochondria (33). Moreover, anti-tumour effect of CoQ<sub>10</sub> administration has also been demonstrated (34). Nevertheless, the gastroprotective effect has not been clarified up to date. In the present study, the protective effect of CoQ<sub>10</sub> against gastric mucosal damage induced by ethanol consumption is determined, particularly after consecutive daily administrations. Possible mechanisms of gastroprotection attributed to the CoQ<sub>10</sub> administration might be as follows: it can act as an antioxidant directly protecting biological membranes against oxidation (4), the antioxidant effect of CoQ species might balance the overproduction of reactive oxygen species by the metabolism of ethanol, CoQ<sub>10</sub> may counteract vasoconstriction resulting from impaired endothelial nitric oxide production (35), and CoQ<sub>10</sub> might maintain gastric mucus thickness.

H<sub>2</sub> blockers and proton pump inhibitors are gastroprotective and anti-ulcerogenic drugs commonly used worldwide. Gastroprotective effects of these drugs are significantly greater when given in high doses. The results of our experimental study either with low or high doses of H<sub>2</sub> blockers were found to be in accordance with the literature. Widespread use of H<sub>2</sub> blockers could not prevent peptic ulcer related disorders. Therefore, the search for new alternatives with novel mechanisms of action is ongoing. In this study, we compared gastroprotective effect of CoQ<sub>10</sub> with those of famotidine as standard treatment option

Histopathological analysis showed that ethanol administration caused gastric mucosal injuries characterized by hemorrhage, mucosal edema, epithelial cell loss, and inflammatory cell infiltration, in accordance with previous studies (9, 18). The lowest histopathological score was observed with Famotidine 20 mg/kg and CoQ<sub>10</sub> given at 30 mg/kg doses for 7 days. The highest his-

topathological score was observed in the ethanol group. These results revealed that the pretreatment with famotidine and CoQ<sub>10</sub> administration diminished gastric mucosal damage. Famotidine has a dose dependent gastroprotective effect, and CoQ<sub>10</sub> leadsto a significant gastroprotection with a 7 days course of repetitive administration. On the other hand, single dose of CoQ<sub>10</sub> administration, even in high doses, did not achieve gastroprotective effect better than the vehicle.

## Conclusion

The present study revealed that oral CoQ<sub>10</sub> pretreatment in repetitive doses for 7 days significantly reduces gastric mucosal injury related to the ethanol application. Soybean oil and single dose of CoQ<sub>10</sub> possess weak gastroprotective potential. Further studies are required to determine the underlying physio-pathological mechanisms that are responsible for the gastroprotective effect of oral CoQ<sub>10</sub> administration.

## References

1. Crane FL, Hafei Y, Lester RL, Widmer C. Isolation of a quinone from beef heart mitochondria. *Biochim Biophys Acta* 1957; 25: 220–221.
2. Ernster L, Dallner G. Biochemical, physiological and medical aspects of ubiquinone function. *Biochim Biophys Acta* 1995; 1271: 195–204.
3. Battino M, Ferri E, Gorini A, Federico Villa R, Rodriguez Huertas JF, Fiorella P et al. Natural distribution and occurrence of coenzyme Q homologues. *Membr Biochem* 1990; 9: 179–190.
4. Molyneux S, Lever M, Florkowski C, George P. Plasma total coenzyme Q9 (CoQ9) in the New Zealand population: reference interval and biological variation. *Clin Chem* 2007; 53: 802–803.
5. Weber C, Bysted A, Hølmer G. The coenzyme Q10 content of the average Danish diet. *Int J Vitam Nutr Res* 1997; 67: 123–129.
6. Shults CW, Haas R. Clinical trials of coenzyme Q10 in neurological disorders. *Biofactors* 2005; 25: 117–126.
7. Karakaya K, Hanci V, Bektas S, Can M, Ucan HB, Emre AU et al., Mitigation o Indomethacin Induced Gastric Mucosal Lesions by a Potent Specific Type V Phosphodiesterase Inhibitor *World J Gastroenterol* 2009; 15: 5091–5096.
8. Kato S, Otaka M, Odashima M, Sato T, Jin M, Matsubashi T et al. Mitigation of Stress-Induced Gastric Mucosal Lesions by a Specific Type IV Phosphodiesterase Inhibitor. *Dig Dis Sci* 2007; 52: 711–716.
9. Yeo M, Kim DK, Cho SW Hong HD. Ginseng, the root of Panax ginseng C.A. Meyer, protects ethanol-induced gastric damages in rat through the induction of cytoprotective heat-shock protein 27. *Dig Dis Sci* 2008; 53: 606–613.
10. Jansson EA, Petersson J, Reinders C, Sobko T, Björne H, Phillipson M et al. Protection from nonsteroidal anti-inflammatory drug (NSAID)-induced gastric ulcers by dietary nitrate. *Free Radic Biol Med* 2007; 42: 510–518.
11. Mizui T, Sato H, Hirose F, Doteuchi M. Effect of antiperoxidative drugs on gastric damage induced by ethanol in rats. *Life Sci* 1987; 41: 755–763.

- 12. Birdane MF, Cemek M, Birdane YO, Gülçin I, Büyükokuroglu ME.** Beneficial effects of *Foeniculum vulgare* on ethanol-induced acute gastric mucosal injury in rats. *World J Gastroenterol* 2007; 13: 607–611.
- 13. Brodie DA, Hanson HM.** A study of the factors involved in the production of gastric ulcers by restraint technique. *Gastroenterology* 1960; 38: 353–361.
- 14. Santucci L, Fiorucci S, Giansanti M, Brunori PM, Di Matteo FM, Morelli A.** Pentoxifylline prevents indomethacin-induced acute gastric mucosal damage in rats – role of tumor-necrosis-factor-alpha. *Gut* 1994; 35: 909–915.
- 15. Fujita Y, Mori I, Kitano S.** Color Reaction between Pyrogallol Red-Molybdenum Complex and Protein. *Bunseki Kagaku* 1983; 32: 379–386.
- 16. Ozveri ES, Bozkurt A, Haklar G, Cetinel S, Arbak S, Yegen C et al.** Estrogens ameliorate remote organ inflammation induced by burn injury in rats. *Inflammation research* 2001; 50: 585–591.
- 17. Arun M, Asha VV.** Gastroprotective effect of *Dodonaea viscosa* on various experimental ulcer models. *Journal of Ethnopharmacology* 2008; 118: 460–465.
- 18. Zhao W, Zhu F, Shen W, Fu A, Zheng L, Yan Z et al.** Protective effects of DIDS against ethanol-induced gastric mucosal injury in rats. *Acta Biochim Biophys Sin* 2009; 41: 301–308.
- 19. Medeiros JVR, Gadelha GG, Lima SJ, Garcia JA, Soares PMG, Santos AA et al.** Role of NO/cGMP/KATP pathway in protective effect of sildenafil against ethanol-induced gastric damage in rats. *Br J Pharmacol* 2008; 153: 722–728.
- 20. Bilici D, Süleyman H, Banoglu ZN, Kiziltunc A, Avci B, Ciftcioglu A, et al.** Melatonin prevents ethanol-induced gastric mucosal damage possibly due to its antioxidant effect. *Dig Dis Sci* 2002; 47: 856–861.
- 21. Birdane MF, Cemek M, Birdane YO, Gülçin I, Büyükokuroglu ME.** Beneficial effects of *Foeniculum vulgare* on ethanol-induced acute gastric mucosal injury in rats. *World J Gastroenterol* 2007; 13: 607–611.
- 22. Matsuhashi T, Otaka M, Odashima M, Jin M, Komatsu K, Wada I et al.** Protective effect of a novel rice extract against ethanol-induced gastric mucosal injury in rat. *Dig Dis Sci* 2007; 52: 434–441.
- 23. Li YG, Ji DF, Lin TB, Zhong S, Hu GY, Chen S.** Protective effect of sericin peptide against alcohol-induced gastric injury in mice. *Chin Med J* 2008; 121: 2083–2087.
- 24. Cho CH, Pfeiffer CJ, Misra HP.** Ulcerogenic mechanism of ethanol and the action of sulphanilic fluoride on the rat stomach in-vivo. *J Pharm Pharmacol* 1991; 43: 495–498.
- 25. Szabo S, Trier JS, Brown A, Schnoor J, Homan HD, Bradford JC.** A quantitative method for assessing the extent of experimental gastric erosions and ulcers. *J Pharmacol Methods* 1985; 13: 59–66.
- 26. Wallace JL, Miller MJ.** Nitric oxide in mucosal defense: a little goes a long way. *Gastroenterology* 2000; 119: 512–520.
- 27. Mosnier P, Rayssiguier Y, Motta C, Pelissier E, Bommelaer G.** Effect of ethanol on rat gastric surfactant: a fluorescence polarization study. *Gastroenterology* 1993; 104: 179–184.
- 28. García Freire IS.** Effect of fats on gastric secretion in a varying degree of innervation of the isolated stomach. (Article in Russian) *Vopr Pitan.* 1980; 1: 49–51 (Abstract).
- 29. Zhang Y, Aberg F, Appelkvist EL, Dallner G, Ernster L.** Uptake of Dietary Coenzyme Q Supplement Is Limited in Rats. *J Nutr* 1995; 125: 446–453.
- 30. Piao H, Hirata A, Yokoyama H, Fujii T, Shimizu I, Ito S et al.** Reduction of gastric ulcerogenicity during multiple administration of diclofenac sodium by a novel solid-in-oil suspension. *Pharm Dev Technol* 2007; 12: 321–325.
- 31. Zhipeng W, Mingkai L, Shuyu C, Min J, Jingru M, Xue M et al.** Toxicity of Coenzyme Q<sub>10</sub>: A report of 90-day repeated dose toxicity study in rats. *J Toxicol Sci* 2007; 32: 505–514.
- 32. Kaikkonen J, Nyssönen K, Tuomainen TP, Ristonmaa U, Salonen JT.** Determinants of plasma coenzyme Q10 in humans. *FEBS Lett* 1999; 443: 163–166.
- 33. Jones K, Hughes K, Mischley L, McKenna DJ.** Coenzyme Q-10: efficacy, safety, and use. *Altern Ther Health Med* 2002; 8: 42–55.
- 34. Folkers K, Brown R, Judy WV, Morita M.** Survival of cancer patients on therapy with coenzyme Q10. *Biochem Biophys Res Commun* 1993; 192: 241–245.
- 35. Rosenfeldt FL, Haas SJ, Krum H, Hadj A, Ng K, Leong JY et al.** Coenzyme Q10 in the treatment of hypertension: meta-analysis of the clinical trials. *J Hum Hypertens* 2007; 21: 297–306.

Received March 6, 2013.

Accepted April 15, 2014.