

The clinical characteristics and the role of surgery and imatinib treatment in patients with liver metastases from c-Kit positive gastrointestinal stromal tumors (GIST)

P. RUTKOWSKI¹, P. NYCKOWSKI², U. GRZESIAKOWSKA³, Z.I. NOWECKI¹, A. NASIEROWSKA-GUTTMEJER⁴, A. PIEŃKOWSKI¹, K. DUDEK², M. KRAWCZYK², W. RUKA¹

¹Department of Soft Tissue/Bone Sarcoma, M. Skłodowska-Curie Memorial Cancer Center and Institute of Oncology, 02-781 Warsaw, e-mail: rutkowskip@coi.waw.pl, ²Department of General and Liver Surgery, Medical University, 02-097 Warsaw, ³Department of Radiology, M. Skłodowska-Curie Memorial Cancer Center and Institute of Oncology, 02-781 Warsaw, ⁴Department of Pathology, M. Skłodowska-Curie Memorial Cancer Center and Institute of Oncology 02-781 Warsaw, Poland

Received April 22, 2003

The purpose of this study was to analyze the clinical features of the group of c-KIT positive GIST patients with liver metastases evaluated and treated in two referral institutions as well as to attempt to define the role of surgery in the management of GIST given the emergence to imatinib as an important part of treatment strategy in GIST patients.

Between August 2001 and December 2002, 90 patients with cKIT positive GIST were referred to our institutions. In 50 patients metastatic disease were disclosed. Of these, 35 patients (35/50; 70%) were rendered to have liver metastases and therefore offered imatinib or surgical therapy depend on CT assessment. The median follow-up of these 35 patients calculated from the time of first operation was 23 months (range 3–246 months).

Male patients comprised the majority of patients (70%) with liver metastases. In 14 patients (40%) the metastases were confined only to the liver, in the others 21 patients (60%) the liver metastases were accompanied by intraperitoneal dissemination (17; 48.6%) or local recurrences (4; 11.4%). The period of time between the diagnosis of primary lesion and occurring liver metastases ranged from 0 to 164 months (median time of liver metastases presentation was 16 months for patients undergone primary curative surgery). The liver metastases were estimated as resectable in 3 cases (8.6%) and hepatic resection of all gross lesions was possible. Group of 32 patients with unresectable liver involvement was considered to treatment with imatinib. The median time of imatinib treatment for survivors is 7.5 months (range: 3.5–18.5 months). Twelve patients (37.5%) demonstrated partial response (PR) and 16 patients (50%) stable disease (SD) according to RECIST criteria. We did not observe any complete response (CR). At median follow-up 7 months, 32 of 35 patients (91.4%) were alive, 3 patients (8.6%) remained free of disease and 28 patients (87.5%) remained on imatinib treatment and have maintained disease although with partial response or stabilization only.

Radical surgical resection remains the only possibility of cure for GIST patients because the complete response after imatinib therapy is restricted to a few patients only. However, despite the advanced metastatic disease, approximately 90% of patients are alive and continue imatinib treatment with median follow-up time more than 7 months. Surgery in combination with adjuvant imatinib treatment may result in improved survival with patients with advanced GIST.

Key words: Gastrointestinal, stromal, tumor, liver, metastases, imatinib.

Gastrointestinal stromal tumors (GIST) compose a recently defined entity of mesenchymal neoplasms of the abdominal cavity and in a majority they develop from alimentary tract. The characteristic feature of these tumors is the overexpression of mutated c-KIT receptor detected by CD117 immunostaining [9, 14, 15, 16, 25, 26]. The results

of new epidemiological studies suggest that GIST is the most common abdominal mesenchymal tumor with the frequency of 16–20 cases/1 million/year [12]. However, the natural history of c-KIT positive GIST patients is not well known. The criteria of malignancy of the primary tumor are not precisely defined. Clinically, despite negative margin

resections (R0), GISTs are characterized by high recurrence rates with intraperitoneal dissemination prevalence and metastatic potential limited almost exclusively to the abdominal cavity [2,19]. All of them are refractory to cytotoxic systemic therapy when disseminated. However the introduction of new targeted therapy has focused attention on GIST patients. It has been shown recently that imatinib, the receptor tyrosine kinase inhibitor e.g. c-KIT, has demonstrated partial response in more than half of treated GIST cases with metastatic and/or unresectable disease [7].

The purpose of this study was to analyze the clinical features of the group of c-KIT positive GIST patients with liver metastases evaluated and treated in two referral institutions. The second goal was to attempt defining the role of surgery in the management of GIST given the emergence to imatinib as an important part of treatment strategy in GIST patients.

Material and methods

Patients with GIST treated in the Department of Soft Tissue/Bone Sarcoma in the M. Skłodowska-Curie Cancer Center and Institute of Oncology (CCI) in Warsaw, Poland in co-operation with the Department of General and Liver Surgery of Medical University (MU) in Warsaw, Poland were evaluated. A prospective collected database was reviewed. The liver metastases from GIST patients were identified. Clinical data, pathologic and surgical reports, and follow-up information were obtained for all patients. End-points analyzed included pattern of failure after 1st operation of GIST and possibility to performance of radical operation at the time of GIST dissemination.

Between August 2001 and December 2002, 90 patients with cKIT positive GIST were referred to our institutions. All pathological diagnoses and CD117 immunostaining (Dako[®]) were confirmed at the Department of Pathology CCI. There were 47 male and 43 female (median age: 57 years; range: 19–79 years). All patients underwent primary surgery. Initial surgical resection included 20 patients (57%) undergoing complete resection (R0), 6 patients (17%) microscopically incomplete resection (R1) and 9 patients (26%) undergoing open biopsy only (R2).

Computed tomography (CT) imaging of the abdominal cavity and pelvis as well as chest X-ray were applied for evaluation of the disease stage. In 50 patients metastatic disease was disclosed. Of these, 35 patients (35/50; 70%) were rendered to have liver metastases and therefore offered imatinib or surgical therapy depend on CT assessment. Imatinib mesylate [Glivec[®]/Gleevec[®]; formerly STI571; small molecule drug of the 2-phenylaminopyrimidine class; Novartis Pharma AG, Basel, Switzerland]. The other patients demonstrated intraperitoneal dissemination. We did not find any lung and lymph node metastases in

these patients. The median follow-up of these 35 patients calculated from the time of first operation was 23 months (range 3–246 months). Each patient considered for imatinib treatment provided informed consent in accordance with institutional regulatory requirements. The imatinib studies were approved by the Bio-Ethics Committee of the CCI.

Results

The characteristics of the group of 35 c-KIT positive GIST patients with liver metastases are shown in Table I. Male patients comprised the majority of patients (70%). All of the primary tumors were in intermediate or high risk group based on tumor size and mitotic count [8]. The most common anatomical sites of tumor origin were the small intestine (42.9%) and the stomach (34.3%). The period of time between the diagnosis of primary lesion and occurring liver metastases was very diverse and the range was 0–164 months. Median time of liver metastases presentation was 16 months for patients undergone primary surgery with curative intention (macroscopic complete resection of all gross disease). In 8 patients (22.9%) liver metastases were presented at diagnosis of the primary disease. In 1 patient histologically confirmed liver metastases were detected 13 years after primary surgery of the gastric tumor.

In 14 patients (40%) the metastases were confined only to the liver, in the others 21 patients (60%) the liver metastases were accompanied by intraperitoneal dissemination (17; 48.6%) or local recurrences (4; 11.4%).

Twelve patients (34.3%) due to liver involvement were

Table 1. Characteristics of 35 GIST patients with liver metastases

Age (years)	
median	55
range	36–79
Gender	
female	11 (31.4%)
male	24 (68.6%)
Primary GIST site	
stomach	12 (34.3%)
small intestine	15 (42.9%)
large intestine	2 (5.7%)
intraperitoneal	4 (11.4%)
retroperitoneal	2 (5.7%)
Number of surgical operations	
1 operation	26 (74.3%)
>1 operation	9 (25.7%)
Pattern of dissemination	
liver metastases only	14 (40%)
liver/intraperitoneal dissemination	17 (48.6%)
liver/local recurrence	4 (11.4%)

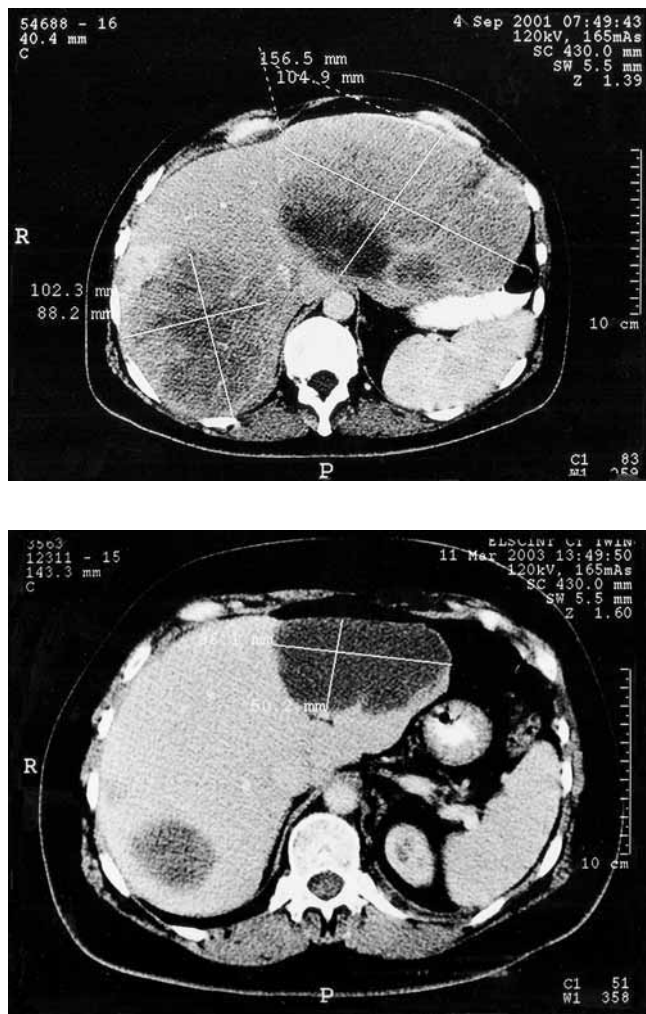


Figure 1. Partial response of multiple liver metastases during 18 months of imatinib treatment: A. – before treatment (4 September 2001) and B – after 18 month of therapy with imatinib (11 March 2003).

treated with chemotherapy (including cytostatic drugs: ifosfamide, cisplatin, doxorubicin and cyclophosphamide in different combinations and schedules). Systemic chemotherapy was administered in 9 cases, and locoregional chemotherapy (hepatic artery infusion) in 3 cases. All patients treated with chemotherapy demonstrated progression of the disease.

The liver metastases were estimated as resectable in 3 cases (8.6%) and hepatic resection of all gross lesions was possible. One patient underwent right hemihepatectomy, two patients underwent not anatomical resection of metastases: 3 lesions in segments IV, VI and VIII were resected in the first patient and 2 liver metastases and concomitant 3 intraperitoneal lesion (undisclosed in preoperative spiral CT) were resected simultaneously. During the short follow-up time (range: 2–6 months) these patients had no evidence of recurrent disease.

Group of 32 patients with massive, unresectable liver involvement was considered to treatment with imatinib. The median time of imatinib treatment for survivors was 7.5 months (range: 3.5–18.5 months). The evaluation of responses to the treatment was made according to RECIST criteria based on CT scans performed every 2–3 months. There were 4 patients (12.5%) with progressive disease (PD) during imatinib treatment [3 patients died, 1 patient after increasing the imatinib dose from 400 mg daily orally to 800 mg daily orally showed partial response of liver metastases], 12 patients (37.5%) with stable disease (SD) and 16 patients (50%) with partial response (PR) (Fig. 1). One patient with PR is currently evaluated for resection of residual disease in the liver, because CT scans showed impressive response and the lesion was made resectable. Imatinib treatment toxicity was mild and tolerable in most of the patients. In two cases we observed grade 3 toxicity: skin purpura and ascites. One patient demonstrated bleeding from the biopsy site in the liver, what required surgical treatment.

At median follow-up 7 months, 32 of 35 patients (91.4%) were alive, 3 patients (8.6%) remained free of disease and 28 patients (87.5%) remained on imatinib treatment and have maintained disease although with partial response or stabilization only.

Discussion

Currently GIST is the most often diagnosed malignant mesenchymal tumor of the gastrointestinal tract. The biologic behavior of these heterogenous neoplasms is difficult to predict. The classification of malignant behavior based on mitotic activity, size and primary tumor anatomic site is not precise [8, 13, 18]. The only absolute criterion for malignancy is the presence of metastases or adjacent organs involvement. The most common site of metastases is the liver (70% of first-site metastases in our series of patients) and therefore treatment of GIST liver metastases become important indication for liver resection. However, patients with liver metastases from GIST demonstrate often bulky, diffuse, advanced liver involvement or presentations of liver metastases may be accompanied by synchronous local recurrences or intraperitoneal dissemination and therefore may be inoperable. The treatment of liver metastases from GIST remains a challenge for experienced oncologists and surgeons [21].

The natural history of c-KIT positive GIST patients is not well known. The presented analysis was made with the attempt to characterize the group of c-KIT positive GIST patients with liver metastases, what may be important to evaluate treatment outcomes of future adjuvant therapy trials.

GIST predominantly occurs in individuals at the age over

40 years and almost equal sex proportions are noted or the incidence is slightly higher in men than women in large series of GIST patients. In our group of patients with liver metastases from GIST the significant prevalence of male patients was observed. GIST may occur anywhere in the gastrointestinal tract (the most common sites are the stomach and the small intestine), although GIST may arise in small proportions also in extra-gastrointestinal locations (omentum, retroperitoneum) [16].

Surgical treatment remains the most important therapeutic approach in GIST patients with primary tumor [2, 11, 24], but the prognosis of GIST has been considered poor with the 5-year specific survival time reported as 28–65% in the most relevant published series of patients [1, 4, 19, 22, 28]. The ability to achieve a complete resection (R0/R1) is one of the main predictor of recurrence of the disease. Recurrence following a complete resection in high risk tumors is common with recurrence rates reported as high as 90% within median follow-up of 68 months after potentially curative surgery [19]. The liver is the predominant site of GIST distant metastases [3, 23]. The median time to the presentation of liver metastases in our patients was 16 months, what is a little shorter period of time than in other reports, which nevertheless took into consideration also the patients with intraperitoneal dissemination only [19, 27]. This discrepancy may be caused by the later detection of intraperitoneal than liver metastases with the use of computed tomography or magnetic resonance imaging (false negative results). It is worth to mention that liver recurrence may also occur many years after the primary tumor resection. These features are different than in other soft tissue sarcomas, where the majority of recurrences develop during the first 2 years after the primary treatment.

Surgical treatment in disseminated disease is less effective [2, 3], because more than 90% of patients after surgical removal of metastatic/locally recurrent lesions demonstrate recurrent disease [24]. The historical results of treatment of recurrent GIST show median survival only 15 months [17]. As it is confirmed in our paper most of the liver metastases in GIST are unresectable due to diffuse, massive intrahepatic disease. However it was reported that even in this low percentage of patients undergone hepatic resection the 3-year survival rate was 58% [5].

Other treatment options have been limited in GIST metastases. The introduction of selective inhibitor of tyrosine kinase receptors – imatinib to clinical practice revolutionized the treatment of GISTs [10, 30]. Results of recent clinical trials demonstrated remarkable high rate of durable remissions in metastatic/inoperable c-KIT positive GIST after imatinib treatment. This first active agent in metastatic GIST is effective at doses from 400 to 800 mg/day orally. The major toxicities include mild fatigue, anemia and edema. In our group of patients in one case bleeding from the biopsy site was noted, but after relaparotomy it was stopped

and the patient recovered well. It could be associated with massive tumor necrosis induced by the drug. Although clinical benefits of imatinib therapy are obvious, only few patients with unresectable or metastatic GIST demonstrated complete response to therapy. Most of them showed partial response or stable disease only. In our study of 32 patients receiving imatinib for measurable disease all had persistent disease: 50% of cases demonstrated partial response and 9.4% of cases progressed and died despite therapy. Despite the advanced metastatic disease approximately 90% of patients are alive and continue imatinib treatment. It is a little higher than reported (88% by DEMETRI et al [6, 7], 82% by VAN OOSTEROM et al [20]), but also the median follow-up time in our group of patients is shorter (7.5 months).

Taking into account that only small percentage of complete remissions after imatinib treatment is noted and surgery alone is inadequate for the treatment of metastatic GIST, the multimodal strategies should be explored [29]. It seems that some patients may become resectable after imatinib treatment and therefore to combine imatinib and surgical therapy seems justified. The role of adjuvant treatment with imatinib in high risk c-KIT positive GISTs is being evaluated in ACOSOG and ACRIN trials [2].

The drug supply was supported by Novartis, Poland.

We thank E. BYLINA and D. RATAJ for assistance in the GIST patients care and M. SYMONIDES for translation assistance.

References

- [1] CLARY BM, DEMATTEO RP, LEWIS JJ, LEUNG D, BRENNAN MF. Gastrointestinal stromal tumors and leiomyosarcomas of the abdomen and retroperitoneum: a clinical comparison. *Ann Surg Oncol* 2001; 8: 290–299.
- [2] DEMATTEO RP. The GIST of targeted cancer therapy: a tumor (gastrointestinal stromal tumor), a mutated gene (c-kit), and a molecular inhibitor (STI 571). *Ann Surg Oncol* 2002; 9: 831–839.
- [3] DEMATTEO RP, HEINRICH MC, EL-RIFAI WM, DEMETRI G. Clinical management of gastrointestinal tumors: before and after STI-571. *Human Pathology* 2002; 33: 466–477.
- [4] DEMATTEO RP, LEWIS JJ, LEUNG D, MUDAN SS, WOODRUFF JM, BRENNAN MF. Two hundred gastrointestinal stromal tumors. Recurrence patterns and prognostic factors for survival. *Ann Surg* 2000; 231: 51–58.
- [5] DEMATTEO RP, SHAH A, FONG Y, JARNAGIN WR, BLUMGART LH, BRENNAN MF. Results of hepatic resection for sarcoma metastatic to the liver. *Ann Surg* 2001; 234:40–548.
- [6] DEMETRI GD. Identification and treatment of chemoresistant inoperable or metastatic GIST: experience with the selective tyrosine kinase inhibitor imatinib mesilate (STI571) *Eur J Cancer* 2002; 38 Suppl 5: S52–S59.
- [7] DEMETRI GD, VON MEHREN M, BLANKE CD, VAN DEL ABEELE AD, EISENBERG B, ROBERTS PJ, HEINRICH MC, TUVESON DA,

- SINGER S, JANICEK M, FLETCHER JA, SILVERMAN SG, SILBERMAN SL, CAPDEVILLE R, KIESE B, PENG B, DIMITRIJEVIC S, DRUCKER BJ, CORLESS C, FLETCHER CDM, JOENSUU H. Efficacy and safety of imatinib mesylate in advanced gastrointestinal stromal tumors. *NEJM* 2002; 347: 472–480.
- [8] FLETCHER CDM, BERMAN JJ, CORLESS C, GORSTEIN F, LASOTA J, LONGLEY BJ, MIETTINEN M, O'LEARY TJ, REMOTTI H, RUBIN BP, SHMOOKLER B, SOBIN LH, WEISS SW. Diagnosis of gastrointestinal stromal tumors: a consensus approach. *Human Pathology* 2002; 33: 459–465.
- [9] HIROTA S, ISOZAKI K, MORIYAMA Y, HASHIMOTO K, NISHIDA T, ISHIGURO S, KAWANO K, HANADA M, KURATA A, TAKEDA M, MUHAMMAD TUNIO G, MATSUZAWA Y, KANAKURA Y, SHINOMURA Y, KITAMURA Y. Gain-of-function mutations of c-kit in human gastrointestinal stromal tumors. *Science* 1998; 279: 577–580.
- [10] JOENSUU H, ROBERTS PJ, SARLOMO-RIKALA M, ANDERSSON LC, TERVAHARTIALA P, TUVESON D, SILBERMAN S, CAPDEVILLE R, DIMITRIJEVIC S, DRUCKER B, DEMETRI GD. Effect of the tyrosine kinase inhibitor STI571 in a patient with a metastatic gastrointestinal stromal tumor. *NEJM* 2001; 344: 1052–1056.
- [11] KIM CJ, DAY S, YEH KA. Gastrointestinal stromal tumors: analysis of clinical and pathologic factors. *Am Surg* 2001; 67: 135–137.
- [12] KINDBLUM LG. Incidence and prevalence of GIST: practical considerations. Conference “Glivec-First Successful Systemic Treatment for GIST”, London 18–20 September 2002.
- [13] MIETTINEN M, EL-RIFAI W, SOBIN LH, LASOTA J. Evaluation of malignancy and prognosis of gastrointestinal tumors: a review. *Human Pathology* 2002; 33: 478–483.
- [14] MIETTINEN M, LASOTA J. Gastrointestinal stromal tumors – definition, clinical, histological, immunohistochemical, and molecular genetic features and differential diagnosis. *Virchows Arch* 2001; 438: 1–12.
- [15] MIETTINEN M, MAJIDI M, LASOTA J. Pathology and diagnostic criteria of gastrointestinal stromal tumors (GISTs): a review. *Eur J Cancer* 2002; 38 Suppl 5: S39–S51.
- [16] MIETTINEN M, MONIHAN JM, SARLOMO-RIKALA M, KOVATICH AJ, CARR NJ, EMORY TS, SOBIN LH. Gastrointestinal stromal tumors/smooth muscle tumors/GISTs in the omentum and mesentery – clinicopathologic and immunohistochemical study of 26 cases. *Am J Surg Pathol* 1999; 23: 1109–1118.
- [17] MUDAN SS, CONLON KC, WOODRUFF J, LEWIS JJ, BRENNAN MF. Salvage surgery in recurrent gastrointestinal sarcoma: prognostic factors to guide patients selection. *Cancer* 1999; 88: 66–74.
- [18] MURO-CACHO CA, CANTOR AB, MORGAN M. Prognostic factors in malignant gastrointestinal stromal tumors. *Ann Clin Lab Sci* 2000; 30: 239–247.
- [19] NG E, POLLOCK RE, MUNSELL MF, ATKINSON EN, ROMSDAHL MM. Prognostic factors influencing survival in gastrointestinal leiomyosarcomas. *Ann Surg* 1992; 215: 68–77.
- [20] VAN OOSTEROM AT, JUDSON I, VERWEIJ J, STROOBANTS S, DUMEZ H, DONATO DI PAOLA E, SCIOT R, VAN GLABBEKE M, DIMITRIJEVIC S, NIELSEN OS. Update of phase I study of imatinib (STI571) in advanced soft tissue sarcomas and gastrointestinal stromal tumors: a report of the EORTC Soft Tissue and Bone Sarcoma Group. *Eur J Cancer* 2002; 38 Suppl 5: S83–S87.
- [21] PATEL SR, BENJAMIN RS. Management of peritoneal and hepatic metastases from gastrointestinal stromal tumors. *Surg Oncol* 2000; 9: 67–70.
- [22] PIERIE JP, CHOUDRY U, MUZIKANSKY A, YEAP BY, SOUBA WW, OTT MJ. The effect of surgery and grade on outcome of gastrointestinal stromal tumors. *Arch Surg* 2001; 136: 383–389.
- [23] PLAAT BE, HOLLEMA H, MOLENAAR WM, BROERS GHT, PIPE J, MASTIK MF, HOEKSTRA HJ, VAN DEN BERG E, SCHEPER RJ, VAN DER GRAAF WTA. Soft tissue leiomyosarcomas and malignant gastrointestinal stromal tumors: differences in clinical outcome and expression of multidrug resistance proteins. *J Clin Oncol* 2000; 18: 3211–3220.
- [24] ROBERTS PJ, EISENBERG B. Clinical presentation of gastrointestinal stromal tumors and treatment of operable disease. *Eur J Cancer* 2002; 38 Suppl 5: S37–S38.
- [25] VAN ROGGEN G, VAN VELTHUYSEN ML, HOGENDOORN PC. The histopathological differential diagnosis of gastrointestinal stromal tumors. *J Clin Pathol* 2001; 54: 96–102.
- [26] SARLOMO-RIKALA M, KOVATICH AJ, BARUSEVICIUS A, MIETTINEN M. CD117: a sensitive marker for gastrointestinal stromal tumors that is more specific than CD 34. *Mod Pathol* 1998; 11: 28–34.
- [27] SCAIFE CL, HUNT KK, PATEL S, BENJAMIN RS, BURGESS MA, CHEN L, TRET J, RAYMOND AK, CORMIER JN, PISTERS PW, POLLOCK RE, FEIG BW. The natural history of cKIT+ gastrointestinal stromal tumors. *Ann Surg Oncol* 2003; 10 Suppl 1 Abstract 93: S37.
- [28] SHIU MH, FARR GH, PAPACHRISTOU DN, HAJDU SI. Myosarcomas of the stomach: natural history, prognostic factors and management. *Cancer* 1982; 49: 177–187.
- [29] SILBERMAN S, JOENSUU H. Overview of issues related to imatinib therapy of advanced gastrointestinal stromal tumors: a discussion among experts. *Eur J Cancer* 2002; 38 Suppl 5: S66–S69.
- [30] TUVESON DA, WILLIS NA, JACKS T, GRIFFIN JD, SINGER S, FLETCHER CD, FLETCHER JA, DEMETRI GD. STI571 inactivation of the gastrointestinal stromal tumor c-kit oncoprotein: biological and clinical implications. *Oncogene* 2001; 20: 5054–5058.