

EXPERIMENTAL STUDY

The effects of L-carnitine and N-acetylcysteine on carbontetrachloride induced acute liver damage in rats

Cetinkaya A¹, Kantarceken B¹, Bulbuloglu E², Kurutas EB³, Ciralik H⁴, Atli Y³*Department of Gastroenterology, Kahramanmaras Sutcu Imam University, Faculty of Medicine, Kahramanmaras, Turkey. drcetinkaya@yahoo.com*

Abstract: *Aim:* To investigate the effects of L-carnitine (LCAR) and N-acetylcysteine (NAC) on carbon tetrachloride (CCl₄)-induced acute liver damage in rats.

Material and methods: Totally, 40 rats in 5 groups were included in the study. The first group was the control group. Group 2 received CCl₄ (2 ml/kg). Group 3 was given CCl₄ + NAC (150 mg/kg). The rats in the Group 4 were administered CCl₄ + LCAR (100 mg/kg), and the rats in the Group 5 were given CCl₄ + NAC + LCAR. Both CCl₄ and the treatment protocols were administered via intraperitoneal route for 10 days. Tissue oxidative stress and antioxidant markers were investigated in liver tissue and serum liver enzymes were measured.

Results: The levels of blood liver enzymes (ALT and AST) increased significantly in the Group 2. However, they decreased markedly in all treatment groups. While malondialdehyde and myeloperoxidase levels in the liver tissue samples increased significantly in the 2nd group, those levels were determined to be decreased significantly in all treatment groups. When the liver tissue antioxidant levels were evaluated; reduced glutathione and catalase decreased markedly in the 2nd group, but increased following the administration of NAC and LCAR. The activities of liver tissue superoxide dismutase did not differ significantly among the groups. In the histopathologic evaluation of liver tissues, on the other hand, diffuse hepatosteatosis was observed in all groups except the control group and there was no significant difference among the groups from the point of steatosis.

Conclusion: LCAR and NAC were concluded to have beneficial effects on the acute liver damage induced by CCl₄ administration (Tab. 1, Fig. 5, Ref. 52). Text in PDF www.elis.sk.

Key words: carbontetrachloride, oxidative stress, liver damage, l-carnitine, n-acetylcysteine.

The acute effect of carbon tetrachloride (CCl₄) causes morphological changes in hepatocyte endoplasmic reticulum (1). The toxic effect of CCl₄ on the liver is explained by the free radical (CCl₃) formed by the biotransformation of the former, resulting in lipid peroxidation (2, 3). When the free oxygen radicals formed as the result of this toxic effect enter into a reaction with unsaturated acids of the lipids in cell membranes, the membranes are destroyed. Lipid breakdown products formed by lipid peroxidation may eliminate sulphhydryl groups of various enzymes and other proteins. Lipid peroxidation may also lead to the breakdown of lysosomal membrane and thus, destructive enzymes may spill into the cytoplasm. CCl₄ causes hydropic degeneration, steatosis and hepatocellular zone 3 necrosis (4).

L-carnitine (LCAR) is an antioxidant and prevents the accumulation of end products of lipid peroxidation (6). In order to explain

the effects of carnitine, several mechanisms have been proposed. Carnitine (β -hydroxy-*N*-trimethylaminobutyric acid) plays a major role, as a cofactor, in the transportation of free fatty acids (FFAs) from the cytosol to the mitochondria. FFAs degrade to acyl-CoA by β -oxidation and these substances enter the tricarboxylic acid (TCA) cycle. A large amount of O₂ is consumed in this reaction and ATP is synthesized in the steps of the electron transport chain and oxidative phosphorylation. O₂ is reduced to H₂O at the end of the TCA cycle and the O₂ concentration decreases. Thus, toxic products such as ROS and products of FFA are cleared from the cell (7). Administration of LCAR stimulates β -oxidation of fatty acids and reduces the esterification of triglycerides (8). Bertelli et al found that LCAR was effective by decreasing liver lipid infiltration and lipid peroxidation in liver damage induced by administration of hyperbaric oxygen and ethanol (9).

N-acetylcysteine (NAC) is the acetylated precursor of both the amino acid L-cysteine and GSH. Historically it has been used as a mucolytic agent in chronic respiratory illnesses as well as an antidote for hepatotoxicity due to acetaminophen overdose (10). More recently, various experimental studies of NAC have shown it to be a powerful antioxidant and a potential therapeutic agent in the treatment of cancer (11), heart disease (12), colitis (13), and pancreatitis (14), characterized by free-radical oxidant damage. On the other hand, beneficial effects of NAC have been demonstrated in acute and chronic liver damage (15, 16).

In view of the above findings, we aimed to demonstrate the

¹Department of Gastroenterology, Kahramanmaras Sutcu Imam University, Faculty of Medicine, Kahramanmaras, Turkey, ²Department of General Surgery, Kahramanmaras Sutcu Imam University, Faculty of Medicine, Kahramanmaras, Turkey, ³Department of Biochemistry, Kahramanmaras Sutcu Imam University, Faculty of Medicine, Kahramanmaras, Turkey, and ⁴Department of Pathology, Kahramanmaras Sutcu Imam University, Faculty of Medicine, Kahramanmaras, Turkey

Address for correspondence: A. Cetinkaya, MD, Department of Gastroenterology, Kahramanmaras Sutcu Imam University, Faculty of Medicine, Kahramanmaras, 46060, Turkey.

Phone: +90.344.2212337/154, Fax: +90.344 2212371

possible beneficial effects of LCAR and NAC on acute liver damage caused by CCl_4 .

Animals and methods

Animals and experimental protocol

The structure of this study and animal experimental procedures were approved by the Ethics Committee of Kahramanmaraş Sutcu Imam University School of Medicine. Forty Wistar albino rats, weighing 160–180 g, were obtained from the Kahramanmaraş Sutcu Imam University School of Medicine Experimental Research Centre (Kahramanmaraş, Turkey). They were kept in stainless steel cages in the animal room, which was maintained on a 12-h-light / 12-h-dark cycle at 21–22 °C. The rats were allowed free access to food and water *ad libitum*.

Wistar rats were divided into five groups (8 rats in each group).

Group I (control): Only 0.2 ml olive oil was given intraperitoneally (IP) to the rats each day throughout ten days.

Group II (CCl_4 Group): 2 ml/kg CCl_4 mixed with olive oil with a rate of 1:1 was given intraperitoneally to the rats for ten days.

Group III (CCl_4 + LCAR Group): 2 ml/kg CCl_4 mixed with olive oil with a rate of 1:1 and 100 mg/kg LCAR were administered intraperitoneally to the rats for ten days.

Group IV (CCl_4 + NAC Group): 2 ml/kg CCl_4 mixed with olive oil with a rate of 1:1 and 150 mg/kg NAC were given intraperitoneally to the rats for ten days.

Group V (CCl_4 + NAC + LCAR Group): 2 ml/kg CCl_4 mixed with olive oil with a rate of 1:1 and additionally 150 mg/kg NAC and 100 mg/kg LCAR were administered intraperitoneally to the rats for ten days.

At the end of the experiment, 3 rats from the Group II and one rat from the Group IV died. Intracardiac blood was drawn from the remaining rats under general anesthesia for biochemical analysis and then they were sacrificed by decapitation. Following sacrifice, liver tissues of the rats were obtained for histopathologic examination and tissue biochemistry. The sera of the blood obtained were separated and kept in –80 °C for later analysis. Liver tissues were kept in formaldehyde solution for histopathologic examination, and in –80 °C for biochemical analysis. Liver tissues were homogenized with 10 volumes of ice-cold 0.25 M sucrose, centrifuged at 14,000 rpm to measure the biochemical parameters in resulting supernatant.

Measurement of Liver Enzymes

Intracardiac blood was drawn from the rats under general anesthesia for biochemical analysis at the end of the experiment and then they were sacrificed. The sera were separated and alanine transaminase (ALT), aspartate transaminase (AST), alkaline phosphatase (ALP) and gamma glutamyl transpeptidase (GGT) levels were analyzed in Immulite 2000 autoanalyzer.

Lipid peroxidation levels

Lipid peroxidation level in the tissue samples was expressed by malondialdehyde (MDA). It was measured according to the

procedure of Ohkawa et al (17). The reaction mixture contained 0.1 ml tissue sample, 0.2 ml of 8.1 % sodium dodecyl sulphate (SDS), 1.5 ml of 20 % acetic acid and 1.5 ml of 0.8 % aqueous solution of thiobarbituric acid. The mixture pH was adjusted to 3.5 and volume was finally made up to 4.0 ml with distilled water and 5.0 ml of the mixture of n-butanol and pyridine (15:1,v/v) was added. The mixture was shaken vigorously. After centrifugation at 4000 rpm for 10 min, the absorbance of the organic layer was measured at 532 nm. MDA level was expressed as nmol/mg protein.

Myeloperoxidase activities

Myeloperoxidase (MPO) activity was determined by a modification of the O-dianisidine method (18). The assay mixture, in a cuvette of 1 cm path length, contained 0.3 ml 0.1 M phosphate buffer (pH 6.0), 0.3 ml 0.01 M H_2O_2 , 0.5 ml 0.02 M O-dianisidine (freshly prepared) in deionized water and 10 microliter supernatant in a final volume of 3.0 ml. The supernatant was added at last and the change in absorbance at 460 nm was followed for 10 min. All measurements were carried out in duplicate. One unit of MPO was defined as that giving an increase in absorbance of 0.001 per min and specific activity was given as U/mg protein.

Superoxide dismutase Activity

Superoxide dismutase (SOD) activity was measured according to the method described by Fridovich (19). This method employs xanthine and xanthine oxidase to generate superoxide radicals, which react with p-iodonitrotetrazolium violet (INT) to form a red formazan dye which was measured at 505 nm. Assay medium consisted 0.01 M phosphate buffer, CAPS (3-cyclohexylamino-1-propanesulfonic acid) buffer solution (50 mM CAPS, 0.94 mM EDTA, satd. NaOH) with pH 10.2, solution of substrate (0.05 Mm xanthine, 0.025 mM INT) and 80 UL xanthine oxidase. SOD activity was expressed as U/mg protein.

Measurement of Glutathione

Reduced glutathione (GSH) level was determined according to method of Beutler (20). The reaction mixture contained filtrate, phosphate buffer and DTNB (5,5'-dithiobis 2-nitrobenzoic acid) in final volume of 10 ml. A blank was also prepared by using precipitating reagent and distilled water instead of filtrate. The absorbances were immediately read in a spectrophotometer at 412 nm before and after addition of DTNB. The values were determined from the standard curve. GSH level was expressed as $\mu\text{mol/mg}$ protein.

Catalase activity

Catalase (CAT) activities were determined by measuring the decrease in hydrogen peroxide concentration at 230 nm by the method of Beutler (20). The assay medium consisted 1 M Tris HCl, 5 mM Na_2EDTA buffer solution (pH 8.0), 1 M phosphate buffer solution (pH 7.0), and 10 mM H_2O_2 . CAT activity was expressed as U/mg protein.

Histopathological Evaluation of Liver Samples

Postmortem liver excision was performed at the end of the experiment and sections of liver tissues were obtained with a thick-

Tab. 1. The effects of LCAR and NAC on the levels of liver enzymes.

	Control Group (n=8)	CCl ₄ Group (n=5)	NAC Group (n=8)	LCAR Group (n=7)	NAC + LCAR Group (n=8)
AST (U/L)	445.5 ± 100.83	1615.8 ± 1058.61*	706.25 ± 225.69**	783.71 ± 170.19	701.75 ± 178.48**
ALT (U/L)	670.5 ± 50.39	1527.4 ± 822.61*	850 ± 211.69	899.85 ± 142.09	817.5 ± 156.17**
ALP (IU/L)	405.12 ± 197.73	393.6 ± 267.79	430.5 ± 200	404.14 ± 173.11	295.25 ± 109.52
GGT (IU/L)	104.5 ± 48.54	135.2 ± 33.97	123.62 ± 60.26	114.57 ± 14.88	228.87 ± 363.1

The data were given as the mean ± SD. * $p < 0.05$, was found statistically significantly higher than control group. ** $p < 0.05$, was found statistically significantly lower than CCl₄ group.

ness of 0.5 cm. The tissue fixed in buffered 10 % formaldehyde was embedded in paraffin blocks. Then 4 μm thick sections were obtained from the blocks and stained with Haematoxylin-Eosin and examined under the light microscope.

Statistical analyses

All data were expressed as the mean ± SD. Groups of data were compared with an analysis of Kruskal-Wallis followed by Mann-Whitney U multiple comparison tests. Values of $p < 0.05$ were regarded as significant.

Results

The levels of ALT and AST were found to be increased significantly in CCl₄ administered group compared to the control and decreased following the addition of either NAC or LCAR. However, the decrease in the levels of ALT and AST was observed to be statistically significant only in LCAR+NAC administered group. On the other hand, the levels of ALP and GGT were found not to differ markedly among the groups (Tab. 1).

When the levels of MDA, determinant of lipid peroxidation, was evaluated, it was found to be increased in CCl₄ group compared to the control and decreased markedly in all treated groups (Group III, IV and V) (Fig. 1). However, no significant difference was detected among the control and treated groups from the point of MDA levels.

When the levels of MPO were evaluated, MPO was found to be increased significantly in CCl₄ group compared to the control and decreased markedly in III, IV and V groups (Fig. 2). No significant difference was detected among the control, III, IV and V. groups.

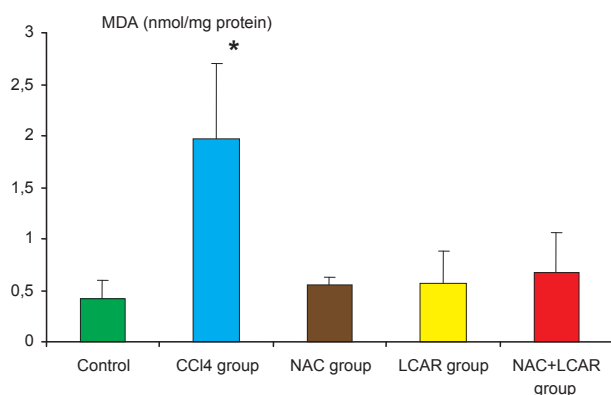


Fig. 1. The effects of LCAR and NAC on the levels of liver MDA. * $p < 0.05$, was found significantly increased than in other groups.

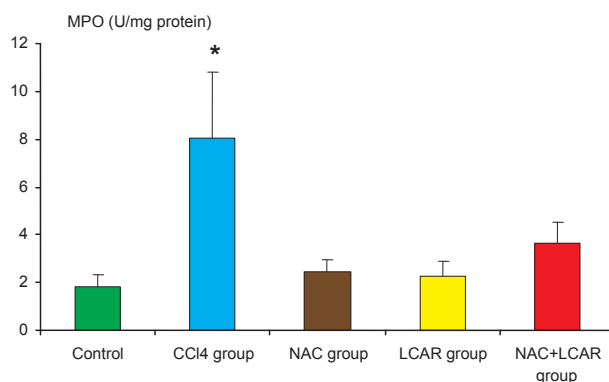


Fig. 2. The effects of LCAR and NAC on the levels of liver MPO. * $p < 0.05$, was found significantly higher than in other groups.

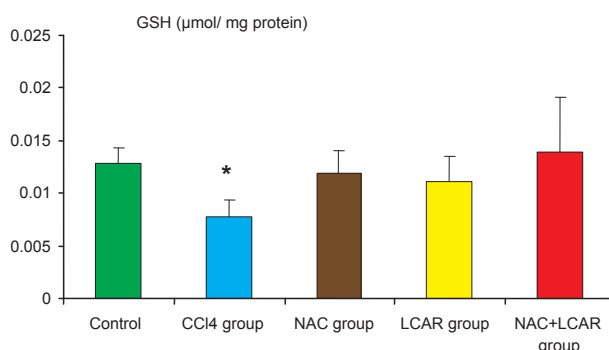


Fig. 3. The effects of LCAR and NAC on the levels of liver GSH. * $p < 0.05$, was found significantly lower than in other groups.

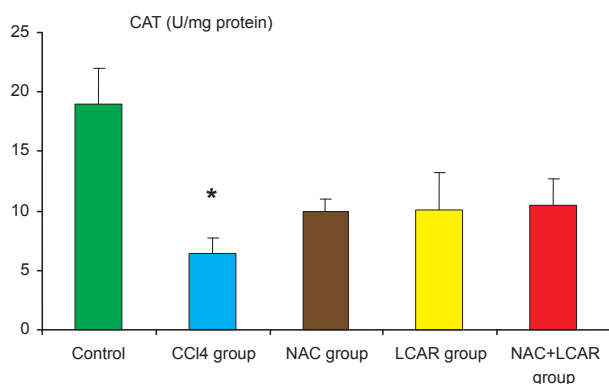


Fig. 4. The effects of LCAR and NAC on the levels of liver CAT. * $p < 0.05$, was found significantly lower than in other groups.

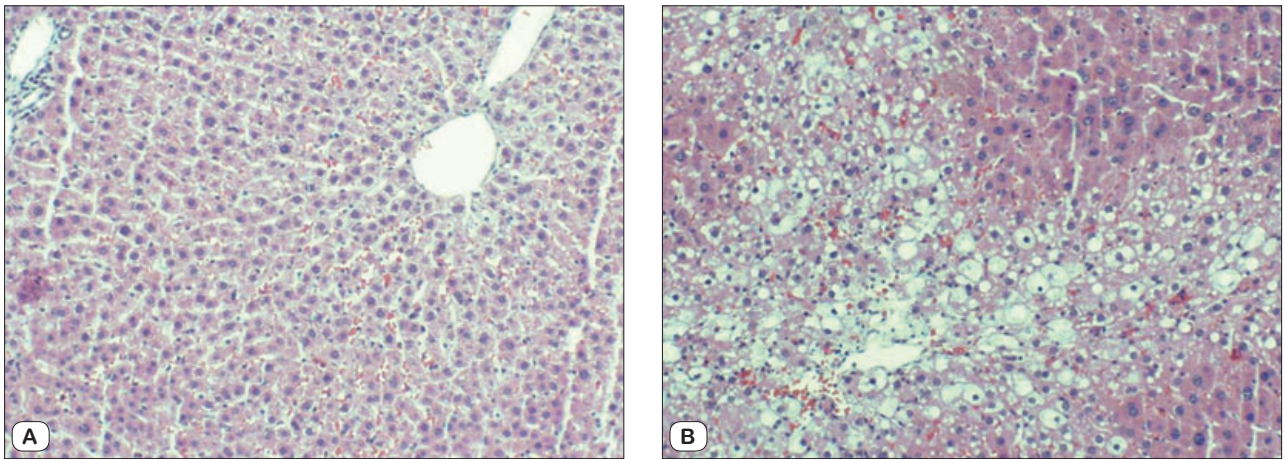


Fig. 5. Representative histological slides from rats receiving saline intraperitoneally (control; A), CCl₄ treatment (B). The liver was cut, embedded in paraffin, and then stained with H&E. Note diffuse steatosis in the liver of CCl₄-treated rats (B). Normal histologic finding was observed in the control (A).

As the markers of antioxidant status, levels of GSH, SOD and CAT were evaluated in the liver tissue. When the levels of GSH in the liver tissue were evaluated, they were found to be decreased significantly in CCl₄ group compared to the control and re-approximated to the levels of control following the treatment with NAC and LCAR (Fig. 3). Also, no significant difference was detected among the control and NAC, LCAR and NAC+LCAR groups.

Similar to the changes in GSH levels, the levels of CAT in the liver tissue decreased significantly in CCl₄ group compared to the control and administration of NAC and LCAR increased the levels of CAT significantly compared to the CCl₄ group (Fig. 4). On the other hand, when the levels of SOD were evaluated, no statistical difference was detected among the groups even though the levels of SOD increased slightly in the CCl₄ and treatment groups compared to the control.

Diffuse steatosis in the liver was observed in histopathologic examination in all groups (Groups II, III, IV and V) but the control. No other pathology was observed except steatosis. There was no significant difference among the groups from the aspect of degree of steatosis (Figs 5A–B).

Discussion

LCAR stimulates beta-oxidation of fatty acids. In case of LCAR deficiency, mitochondrial fatty acid oxidation is impaired and fat deposition occurs in the cytoplasm of liver cells. Deposited fat, in turn, impairs the functions of liver (21). The level of LCAR in the liver tissue was shown to decrease in cases with cirrhosis (22). LCAR, on the other hand, was shown to have protecting effects against lipid peroxidation, steatosis and necrosis in the liver injury caused by ethanol (23). Moreover, antioxidant effects of NAC in various cases in which oxidative stress took part in were shown in many experimental studies (11–14, 24).

NAC was also shown to have beneficial effects in acute and chronic liver injuries. Galicia-Moreno M and co-workers demon-

strated the beneficial effects of NAC through oxidative stress and profibrinogenic mechanisms in experimental liver cirrhosis formed by CCl₄ administration (15). In another study, beneficial effects of NAC and desferoxamin were demonstrated in experimental acute liver damage formed by CCl₄ (16). The effects of NAC and LCAR separately in acute liver injury were investigated. However, any study investigating the effects of both antioxidant agents together could not be found in literature. We found in that thesis a study that NAC and LCAR together decreased the oxidative stress markers and levels of liver enzymes in acute liver injury formed by CCl₄ exposure.

One of the most frequently used agents in forming liver injury in experimental studies is CCl₄ and the free oxygen radicals released during its enzymatic metabolism are the basic factor of cellular injury caused by CCl₄. The cellular injury associated with CCl₄ is caused by either binding of the radicals to the cellular components by covalent bonds or increased lipid peroxidation (25, 26).

Monoxygenase system of the endoplasmic reticulum has a role in the metabolism of CCl₄. Unstable trichlormethyl peroxide complex is structured by the cytochrom p-450 isoenzyme and converted into trichlormethyl peroxide by oxygen (27). The early change in CCl₄ hepatotoxicity takes place as lipid deposition in liver and blockage in lipoprotein secretion (28). Following the damage caused by CCl₄, lipid peroxidation becomes effective. Radicals of CCl₄ were demonstrated to lead lipid changes in the endoplasmic reticulum. Cytotoxic products originating from microsomal lipids of the liver cause diffuse cellular injury (29). Free oxygen radicals and lipid peroxidation as well as other factors are thought to be responsible in the pathogenesis of fatty and infiltrative liver diseases.

LCAR was shown to be deposited in muscle and brain tissue in general in various studies. It is deposited in the liver tissue as well. It was reported that extrarenal excretion of LCAR was increased when LCAR was given intraperitoneally. The main route

for extrarenal excretion of LCAR is the hepatobiliary system. Additionally, LCAR was shown to be exposed to recirculation in the biliary system (30). NAC, on the other hand, passes heavily into the liver tissue after being absorbed. Glutathion, the production of which was induced by NAC, was shown to be deposited substantially in the portal vein in some studies (31, 32).

It has been demonstrated in many recent studies that free oxygen metabolites play a basic role in the mechanism of hepatotoxicity of various substances and medical agents (33–35). Oxidative stress also takes part in the hepatotoxic effect of CCl_4 and its negative effect has been shown through some experimental studies to be alleviated by various antioxidant agents (36–39).

In addition, lipid peroxidation is known to play a basic role in the injury to the cell membrane through free oxygen radicals. MDA is frequently used in the measurement of lipid peroxide levels and is well correlated with the degree of lipid peroxidation (40). The levels of MDA increased due to the hepatotoxic effects of CCl_4 and this increase was demonstrated to slow down with the addition of antioxidant agents such as LCAR and NAC used in our study (15, 16, 41). In addition to the direct damaging effect on the tissues, free radicals are supposed to induce the accumulation of leukocytes in the tissue and hence trigger the tissue injury indirectly through activated neutrophils. It was demonstrated that activated neutrophils accumulated in the inflammation site and secreted MPO to the extracellular spaces and converted hydroperoxides to free radicals and hence initiated lipid peroxidation (42). MPO, which exists in high levels in neutrophils, is used as an efficient digital indicator of inflammation. The level of MDA and activity of MPO were observed to increase significantly in the CCl_4 group compared to the control and to decrease significantly in the treatment groups compared to the control. These results may show that either NAC or LCAR alone, or combined treatment impede the progress of lipid peroxidation injury and degree of inflammation caused by CCl_4 .

On the other hand, as the result of evaluation of liver enzymes, the levels of ALT and AST were shown to increase significantly in CCl_4 group and decrease markedly following the administration of LCAR and NAC. However, the decrease in liver enzymes was statistically significant only in NAC + LCAR group. This result demonstrates that combined therapeutic use of NAC and LCAR is more effective in decreasing the liver enzymes.

GSH is a thiol compound in tripeptide structure, which exists in all mammalian cells and protects the cells against free radicals and toxic metabolites. GSH and other thiol containing compounds provide the cell viability and membrane stability against cellular and tissue injury induced by chemical substances. GSH plays an important role in the detoxification of various drugs and chemical substances. Liver protecting role of thiol compounds such as GSH primarily, was shown in many studies (43–45). The levels of GSH were demonstrated to decrease significantly due to hepatotoxic effects of CCl_4 and this effect was also shown to be lessened by various antioxidant substances (46–48).

GSH and CoA were found to be closely associated with each other (49). Carnitine has an essential role in the release of acyl

groups from CoA. The release of acyl groups is important in the oxidation of alpha ketoglutarate from the metabolization of pyruvate and fatty acids. NAC was shown in various studies to increase the levels of glutathion since it is a sulfhydryl source. In addition, decreased levels of GSH in the liver tissue due to CCl_4 exposure were demonstrated to increase with the treatment of LCAR and NAC in many experimental studies (15). In the current study, it was observed that GSH levels decreased significantly only in CCl_4 group compared to the control and approximated to the control levels again by increasing following the administration of LCAR and NAC.

SOD bears an essential role for the protection against oxidative stress (50). It is a metalloprotein inducing the conversion of superoxide to hydrogen peroxide and hence prevents the formation of free radicals. On the other hand, CAT is an enzyme responsible for the detoxification of hydrogen peroxide under the catalyzing effect of SOD. In our study, SOD activity was demonstrated not to show any change in both CCl_4 and treatment groups, however, the levels of CAT were found to decrease markedly due to administration of CCl_4 and increase again significantly following the treatment with NAC and LCAR. In the previous experimental liver injury studies conducted by CCl_4 , the levels of SOD and CAT were detected to decrease and later increase after the treatment with antioxidant agents. However, in some other studies, SOD levels were determined not to change significantly parallel to the results obtained in our study (51, 52).

In the histopathological results of our study, only diffuse hepatosteatosis was determined as one of the acute effects of CCl_4 . Moreover, no significant difference was detected between the CCl_4 and treatment groups from the aspect of hepatosteatosis. Furthermore, other findings such as necrosis, inflammation or fibrosis detected in some other studies were not observed in our study. Since the histopathological response was inconclusive even though the biochemical results obtained were remarkable, it was thought that the toxicity period was insufficient and long-term toxicity studies with different doses of antioxidant treatment would be beneficial in further research.

In conclusion, antioxidant LCAR and NAC have liver protecting features against acute liver damage formed by CCl_4 according to the results obtained in this study. On the other hand, it was demonstrated that transaminase levels (ALT, AST) which are markers of liver damage increased significantly by CCl_4 and decreased effectively especially in NAC and LCAR combination group. Furthermore, no additional pathology was found except diffuse steatosis in histopathologic examination in both injury model and treatment groups. No significant difference was observed among the groups in the histopathologic examination. Therefore, studies investigating more prolonged toxicity models and treatment options with different doses were thought to be beneficial. This study was concluded to lead the usage of novel medications as a supplementary therapy in the treatment of acute liver failure.

References

- Cagen SZ, Klaasen CD.** Carbon tetrachloride-induced hepatotoxicity: studies in developing rats and protection by zinc. *Fed Proc* 1980; 39 (13): 3124–3128.
- Masaki N, Yamada S, Ogata I, Ohta Y, Fujiwara K.** Enhancement of carbon tetrachloride-induced liver injury by glucagon and insulin treatment. *Res Exp Med (Berl)* 1988; 188 (1): 27–33.
- Simeonova PP, Gallucci RM, Hulderman T, Wilson R, Kommineni C, Luster MI.** The role of tumor necrosis factor alpha in liver toxicity, inflammation, and fibrosis induced by carbon tetrachloride. *Toxicol Appl Pharmacol* 2001; 177 (2): 112–120.
- Poli G, Cottalasso D, Pronzato MA, Chiarpotto E, Marinari UM.** Lipid peroxidation and covalent binding in the early functional impairment of golgi apparatus by carbon tetrachloride. *Cell Biochem Funct* 1990; 8 (1): 1–10.
- Poli G, Albano E, Dianzani MU.** The role of lipid peroxidation in liver damage. *Chem Phys Lipids* 1987; 45 (2–4): 117–42.
- Lowitt S, Malone JI, Salem AF, Korhals J, Benford S.** Acetyl-L-carnitine corrects the altered peripheral nerve function of experimental diabetes. *Metabolism* 1995; 14 (5): 677–680.
- Mayes PA.** Lipids of physiologic significance. *In Harper's Biochemistry*. Murray, RK, Granner DK, Mayes PA, Rodwell VW (Eds.). Stanford, CA, McGraw-Hill, 2000, pp 160–171.
- Maebashi GF, Sato M, Kawamura N, Imamura A, Yoshinaga K.** Lipid-lowering effect of carnitine in patients with type IV hyperlipoproteinemia. *Lancet* 1978; 2 (8094): 805–807.
- Bertelli A, Cerrati A, Giovannini L, Mian M, Spaggiari P, Bertelli AE.** Protective action of L-carnitine and coenzyme Q10 against hepatic triglyceride infiltration induced by hyperbaric oxygen and ethanol. *Drugs Exp Clin Res* 1993; 19 (2): 65–68.
- De Vries N, De Flora S.** N-Acetyl-L-Cysteine. *J Cell Biochem Suppl* 1993; 17F: 270–277.
- Kobrinsky NL, Sjolander DE, Goldenberg JA, Ortmeier TC.** Successful treatment of doxorubicin and cisplatin resistant hepatoblastoma in a child with Beckwith-Wiedemann syndrome with high dose acetaminophen and N-acetylcysteine rescue. *Pediatr Blood Cancer* 2005; 45 (2): 222–225.
- Rodrigues AJ, Evora PR, Schaff HV.** Protective effect of N-acetylcysteine against oxygen radical-mediated coronary artery injury. *Braz J Med Biol Res* 2004; 37 (8): 1215–1224.
- Akgun E, Caliskan C, Celik HA, Ozutemiz AO, Tuncyurek M, Aydin HH.** Effects of N-acetylcysteine treatment on oxidative stress in acetic acid-induced experimental colitis in rats. *J Int Med Res* 2005; 33 (2): 196–206.
- Yagci G, Gul H, Simsek A et al.** Beneficial effects of N-acetylcysteine on sodium taurocholate-induced pancreatitis in rats. *J Gastroenterol* 2004; 39 (3): 268–276.
- Galicía-Moreno M, Rodríguez-Rivera A, Reyes-Gordillo K et al.** N-acetylcysteine prevents carbon tetrachloride-induced liver cirrhosis: role of liver transforming growth factor-beta and oxidative stress. *Eur J Gastroenterol Hepatol* 2009; 21 (8): 908–924.
- Ritter C, Reinke A, Andrades M, et al.** Protective effect of N-acetylcysteine and deferoxamine on carbon tetrachloride-induced acute hepatic failure in rats. *Crit Care Med* 2004; 32 (10): 2079–2083.
- Ohkawa H, Ohishi N, Tagi K.** Assay for lipid peroxides in animal tissues by thiobarbituric acid reaction. *Anal Biochem* 1979; 95 (2): 351–358.
- Worthington Enzyme Manual.** Worthington Biochemical Corporation. Freehold, New Jersey, USA, 1972.
- Fridovich I.** Superoxide radical: an endogenous toxicant. *Annu Rev Pharmacol Toxicol* 1983; 23: 239–257.
- Beutler E.** *Red Cell Metabolism*. New York, Grune and Stratton, 1975.
- Lundholm K, Persson H, Wennberg A.** Whole body fat oxidation before and after carnitine supplementation in uremic patients on chronic haemodialysis. *Clin Physiol* 1988; 8 (4): 417–426.
- Selimoglu MA, Aydogdu S, Yagci RV, Huseyinov A.** Plasma and liver carnitine status of children with chronic liver disease and cirrhosis. *Pediatr Int* 2001; 43 (4): 391–395.
- Bahcecioglu IH, Demir A, Ustundag B et al.** Protective effect of L-carnitine on alcoholic fatty liver in rats. *Med Sci Res* 1999; 27: 475–478.
- Cetinkaya A, Bulbuloglu E, Kurutas EB, Ciralik H, Kantarcekren B, Buyukbese MA.** Beneficial effects of N-acetylcysteine on acetic acid-induced colitis in rats. *Tohoku J Exp Med* 2005; 206 (2): 131–139.
- Bruckner JV, MacKenzie WF, Muralidhara S, Luthra R, Kyle GM, Acosta D.** Oral toxicity of carbon tetrachloride: acute, subacute, and subchronic studies in rats. *Fundam Appl Toxicol* 1986; 6 (1): 16–34.
- Boll M, Weber LW, Becker E, Stampfl A.** Mechanism of carbon tetrachloride-induced hepatotoxicity. Hepatocellular damage by reactive carbon tetrachloride metabolites. *Z Naturforsch C* 2001; 56 (7): 649–659.
- Recknagel RO, Glende EA, Dolak JA, Waller RL.** Mechanisms of carbon tetrachloride toxicity. *Pharmacol Ther* 1989; 43 (1): 139–154.
- Brattin WJ, Glende EA, Recknagel RO.** Pathological mechanisms in carbon tetrachloride hepatotoxicity. *J Free Radic Biol Med* 1985; 1 (1): 27–38.
- Rikans LF, Hornbrook KR, Cai Y.** Carbon tetrachloride hepatotoxicity as a function of age in female fischer 344 rats. *Mech Ageing Dev* 1994; 76 (2–3): 89–99.
- Rizza V, Lorefice R, Rizza N et al.** Pharmacokinetics of L-carnitine in human subjects. *In: Ferrari R, Daimura S, Sherwood G, eds. L-Carnitine and its Role in Medicine: From Function to Therapy*. San Diego: Academic Press, 1992; 63–80.
- Cotgreave IA, Berggren M, Jones TW, Dawson J, Moldéus P.** Gastrointestinal metabolism of N-acetylcysteine in the rat, including an assay for sulfite in biological systems. *Biopharm Drug Dispos* 1987; 8 (4): 377–386.
- Kelly GS.** Clinical applications of N-acetylcysteine. *Altern Med Rev* 1998; 3 (2): 114–127.
- Kumar O, Sugendran K, Vijayaraghavan R.** Oxidative stress associated hepatic and renal toxicity induced by ricin in mice. *Toxicol* 2003; 1 (3): 333–338.
- Akhgari M, Abdollahi M, Kebryaezadeh A, Hosseini R, Sabzevari O.** Biochemical evidence for free radical-induced lipid peroxidation as a mechanism for subchronic toxicity of malathion in blood and liver of rats. *Hum Exp Toxicol* 2003; 22 (4): 205–211.
- Tafazoli S, Spehar DD, O'Brien PJ.** Oxidative stress mediated idiosyncratic drug toxicity. *Drug Metab Rev* 2005; 37 (2): 311–325.
- Ye X, Feng Y, Tong Y et al.** Hepatoprotective effects of Coptidis rhizoma aqueous extract on carbon tetrachloride-induced acute liver hepatotoxicity in rats. *J Ethnopharmacol* 2009; 124 (1): 130–136.

37. **Murugesan GS, Sathishkumar M, Jayabalan R, Binupriya AR, Swaminathan K, Yun SE.** Hepatoprotective and curative properties of Kombucha tea against carbon tetrachloride-induced toxicity. *J Microbiol Biotechnol* 2009; 19: 397–402.
38. **Yadav NP, Pal A, Shanker K, Bawankule DU, Gupta AK, Darokar MP, S Khanuja SP.** Synergistic effect of silymarin and standardized extract of *Phyllanthus amarus* against CCl₄-induced hepatotoxicity in *Rattus norvegicus*. *Phytomedicine* 2008; 15 (12): 1053–1061.
39. **Pramod K, Deval RG, Lakshmayya, Ramachandra SS.** Antioxidant and hepatoprotective activity of tubers of *Momordica tuberosa* Cogn. against CCl₄ induced liver injury in rats. *Indian J Exp Biol* 2008; 46 (7): 510–513.
40. **Bruce AF and Crapo JD.** Biology of disease. Free radicals and liver injury. *Lab Invest* 1982; 47: 412–426.
41. **Demirdag K, Bahcecioglu IH, Ozercan IH, Ozden M, Yilmaz S, Kalkan A.** Role of L-carnitine in the prevention of acute liver damage induced by carbon tetrachloride in rats. *J Gastroenterol Hepatol* 2004; 19 (3): 333–338.
42. **Panasenko OM, Chekanov AV, Arnhold J, Sergienko VI, Osipov AN, Vladimirov YA.** Generation of free radicals during decomposition of hydroperoxide in the presence of myeloperoxidase or activated neutrophils. *Biochemistry (Mosc)* 2005; 70 (9): 998–1004.
43. **Gokce G, Ozsarlak-Sozer G, Oktay G, Kirkali G, Jaruga P, Dizardoglu M, Kerry Z.** Glutathione depletion by buthionine sulfoximine induces oxidative damage to DNA in organs of rabbits in vivo. *Biochemistr* 2009; 48 (22): 4980–4987.
44. **Khan MR, Ahmed D.** Protective effects of *Digera muricata* (L.) Mart. on testis against oxidative stress of carbon tetrachloride in rat. *Food Chem Toxicol* 2009; 47 (6): 1393–1399.
45. **Liu Y, Zhang H, Zhang L et al.** Antioxidant N-acetylcysteine attenuates the acute liver injury caused by X-ray in mice. *Eur J Pharmacol* 2007; 575 (1–3): 142–148.
46. **Quan J, Piao L, Xu H, Li T, Yin X.** Protective effect of iridoid glucosides from *Boschniakia rossica* on acute liver injury induced by carbon tetrachloride in rats. *Biosci Biotechnol Biochem* 2009; 73 (4): 849–854.
47. **Chen L, Pan DD, Zhou J, Jiang YZ.** Protective effect of selenium-enriched *Lactobacillus* on CCl₄-induced liver injury in mice and its possible mechanisms. *World J Gastroenterol* 2005; 11 (37): 5795–5800.
48. **Gui SY, Wei W, Wang H, Wu L, Sun WY, Wu CY.** Protective effect of fufanghuangqiduogan against acute liver injury in mice. *World J Gastroenterol* 2005; 11 (19): 2984–2989.
49. **Sies H, Berstenecker G, Surumer KH, Menzel H, Fabe L.** Glutathione. In: *Proceedings of the 16th Conference of the German Society of Biological Chemistry*. Stuttgart: George Thieme Publisher, 1974.
50. **Loeper J, Goy J, Rozensztajn L, Bedu O, Moisson P.** Lipid peroxidation and protective enzymes during myocardial infarction. *Clin Chim Acta* 1991; 196 (2–3): 119–125.
51. **Mehmetcik G, Ozdemirler G, Kocak-Toker N, Cevikbaş U, Uysal M.** Effect of pretreatment with artichoke extract on carbon tetrachloride-induced liver injury and oxidative stress. *Exp Toxicol Pathol* 2008; 60 (6): 475–480.
52. **Szymonik-Lesiuk S, Czechowska G, Stryjecka-Zimmer M, Słomka M, Madro A, Celiński K, Wielosz M.** Catalase, superoxide dismutase, and glutathione peroxidase activities in various rat tissues after carbon tetrachloride intoxication. *J Hepatobiliary Pancreat Surg* 2003; 10 (4): 309–315.

Received February 12, 2012.

Accepted August 18, 2013.