

CASE REPORT

Reccurent bleeding from Meckel's diverticulum – surgeon's challenge

Hrbaty B, Shilova N, Labas P, Reis R, Cambal M, Kostka V

1st Department of Surgery, University Hospital of Bratislava and Medical Faculty of Comenius University, Bratislava, Slovakia. hrbatyboboh@gmail.com

Abstract: The authors of this paper want to share their experience with diagnostic and therapeutic problems in case of chronic small intestinal bleeding from Meckel's diverticulum, which ended with acute episode of massive gastrointestinal bleeding requiring emergent surgery.

Despite the progress achieved in diagnosing the sources of gastrointestinal bleeding, the diagnosis of small intestinal bleeding is very frequently beyond the ability of making it right, and thus emergent surgery is often the only possibility of saving the patient's life on the one hand, and allowing stating the correct diagnosis on the other (Fig. 1, Ref. 6). Text in PDF www.elis.sk.

Key words: Meckel diverticulum, bleeding, endoscopy, management, diagnosis, surgery, emergent.

Meckel (ileal) diverticulum is a congenital abnormality due to persistence and incomplete occlusion of the proximal part of the omphaloenteric duct. It occurs in 2 % of the population.

This pathology is the most frequently an asymptomatic and incidentally found condition discovered during laparotomy or laparoscopy (1, 2).

Complications can present with hemorrhage, diverticulitis, intussusception, intestinal obstruction and some other relatively rare complications.

One of the most frequent complications is hemorrhage with an incidence of 20 to 30 %. In case of complications of the Meckel's diverticulum, there is no other way of treatment than surgery.

Ileal diverticulum can be easily unnoticed or mistaken for other pathology due to limited abilities of diagnostic procedures related to small bowel pathology.

Material and methods

In this case we present a patient with long-term history of obscure intestinal bleeding. He had undergone a wide spectrum of diagnostic evaluations with no significant findings before he was subdued to emergent surgery during which his condition was surgically identified and his bleeding Meckel's diverticulum removed.

Here we would like to stress the significance of surgical approach and interdisciplinary cooperation in the management of such patients.

Analysis of the case of bleeding Meckel's diverticulum

We present a 31-year-old male patient with a wide medical history of several episodes of obscure intestinal bleeding during a period of four years (2007–2011).

In 2007, then at age of 25 years, the patient was for the first time admitted to the 1st Department of Surgery, University Hospital of Bratislava with an acute episode of melena and iron-deficient anemia with hemoglobin level of 119 g/l and red blood cells count of $3.93 \times 10^{12}/l$.

This patient was managed in cooperation with internal medicine specialists and gastroenterologists. In the first line, he was indicated for gastroscopy, which revealed subcardial erosion and presence of peptic ulcer in the stomach. Adequate resuscitation, hemostyptic and anti-ulcer therapy by means of proton pump inhibitors (PPI) were given and the patient was discharged in good condition from the hospital.

Seven months later, the patient was admitted to the surgical department again with the second episode of melena. This time the patient refused gastroscopy. Symptomatic hemostyptic therapy and PPI were given with appropriate effect and in two days the patient was discharged to be seen at an out-patient department.

In two months, the patient was admitted to hospital with recurrent melena for the third time, and again refused gastroscopy. After a course of anti-ulcer and hemostyptic therapy, the patient was discharged with recommendations of further diagnosis and treatment at the gastroenterologic out-patient department.

For further two years, the patient had no health complications in respect of signs of gastrointestinal bleeding.

In the middle of 2010, the patient presented with the first episode of red blood in stool, upper abdominal pain, and about two weeks of history of pyrosis and fatigue. Hemoglobin level was 94 g/l, and red blood cells count was $3.08 \times 10^{12}/l$. Gastroscopy re-

1st Department of Surgery, University Hospital of Bratislava and Medical Faculty of Comenius University, Bratislava, Slovakia

Address for correspondence: B. Hrbaty, MD, 1st Department of Surgery, University Hospital of Bratislava and Medical Faculty of Comenius University, Bratislava, Slovakia.

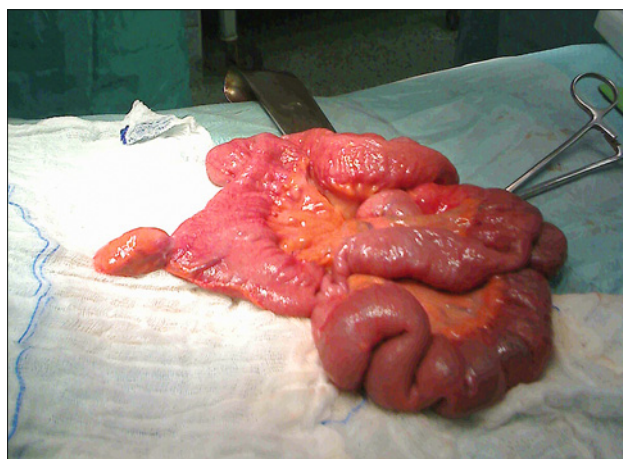


Fig. 1. Meckel's diverticulum.

vealed some small erosions in the fundal part of the anterior gastric wall. On push enteroscopy (proximal 50–60 cm of jejunum), no sign of hemorrhage was discovered. Colonoscopy did not show any pathology either. CT angiography showed mesenteric lymphadenopathy with nodes up to 11x7mm in size, while the size of the largest one was 14x10mm. Apart from this, no source of gastrointestinal bleeding within the small intestine was found. After four days of treatment at the intensive care unit in form of adequate resuscitation, anti-ulcer, hemosubstitution, and hemostyptic therapy, the patient was transferred to the general surgery ward.

Two weeks after complex symptomatic treatment, the patient completely recovered and was discharged.

Four months later, the patient presented with the fifth episode of obscure intestinal bleeding with the same symptoms as mentioned before. Hemoglobin level was 91 g/l, and red blood cells count was $3.02 \times 10^{12}/l$. Colonoscopy, including 15–20 cm of terminal ileum, was performed, and it showed no source of bleeding. The patient was discharged again after a course of hemostyptic and anti-ulcer therapy with hemosubstitution therapy aimed at curing his anemia.

On the last known hospital admission in 2011 (the sixth admission since the beginning of patient's complaints), the 31-year-old patient presented with recurrent bright red blood presented in stool, seven days of history of melena, paleness, and fatigue. Primary examination revealed compensated hemodynamic status with blood pressure at 120/60 Torr, pulse frequency of 90/min, hemoglobin level of 124 g/l, and red blood cells at $4.2 \times 10^{12}/l$. No evidence of acute intestinal hemorrhage was further found on gastroscopy with proximal jejunoscopy, and CT angiography. Colonoscopy revealed only the presence of red blood and blood coagula in the sigmoid colon. Suddenly, massive enterorrhagia started, without any evident source of bleeding. Hemoglobin decreased to 68.2 g/l, red blood cells count decreased to $2.45 \times 10^{12}/l$, and HTC levels were 0.24. The hemodynamic status and performed blood tests clearly showed signs of acute hemorrhagic shock. The patient was transferred to the intensive care unit, where adequate resuscitation, hemosubstitution and hemostyptic therapy were given.

Despite all these measures, the patient's status was getting worse and the patient was referred for an urgent exploratory laparotomy.

Small transrectal laparotomy in the right hypogastrum was performed. Revision of the small intestine revealed the presence of Meckel's diverticulum as an evident source of hemorrhage in a distance of about 60 cm from the ileocecal junction (Fig. 1).

The aboral part of the small intestine had transluminal signs of blood, whereas the oral part showed no signs of blood being present.

The process – the size of Meckel's diverticulum – was 6cm in length and 2.5 cm in width. The remnant part of the small bowel to the ligament of Treitz was without any evidence of any other pathological process. The diverticulum was dissected and the mucosa of the accessible part of the small bowel was checked. Consequently, the continuity of the small intestine was reestablished.

Simultaneously, an appendectomy was performed with no evidence of pathological process on gross examination of specimen. The postoperative period was without any complication; the patient recovered without any incident, and was discharged on third postoperative day.

In the following period of 2.5 years of permanent follow up, the patient had no further episodes of gastrointestinal bleeding.

Conclusion

The episodes of bleeding from Meckel's diverticulum are quite rare due to low incidence of this pathology itself, but not impossible. The problem lies in the unexpectedness of their presence as well as in the difficulty of their diagnostic and therapeutic management. As opposed to modern diagnostic possibilities (enteroscopy, CT, MRI, AG, mesenteric AG, scintigraphy scans, PET...), the diagnosis of acute small intestinal bleeding still persists to be very complicated and frequently impossible to be managed without surgery.

This is the reason, why we want to present our experience with this condition.

Discussion

Gastrointestinal bleeding is a major cause of acute hospital attendance in adults. Nearly 80 % of bleeding in adults originates proximal to the ligament of Treitz. The most common source of the lower gastrointestinal bleeding is colon, while the small intestine is involved in less than 5 %. The usual investigations include upper gastrointestinal endoscopy and colonoscopy as well as the usual biochemical and hematological investigations. Endoscopy may become useless once there is a significant blood pool obstructing the visibility. Technetium-bleeding scan and angiography may be used to diagnose rare focal sources of bleeding such as Meckel's diverticulum (3).

Meckel's diverticulum was first described by Fabricius Hildanus in 1598. The name derives from the German anatomist Johann Friedrich Meckel who described the embryological and pathological features in 1809. Although it generally remains silent, life-threatening complications may arise. Hence, the knowledge

of this structure's anatomical and pathophysiological properties becomes important when dealing with such complications (4, 6).

Meckel's diverticulum is the most common congenital malformation of gastrointestinal tract. It can cause complications in form of ulceration, hemorrhage, intussusception, intestinal obstruction, perforation and, very rarely, vesicodiverticular fistulae, and tumors. These complications, especially bleeding, are more common in the pediatric age group than in adults. Nevertheless it is not uncommon to miss the diagnosis of Meckel's diverticulum in adults (5).

The literature is replete with the description of Meckel's diverticulum for its clinical presentations and complications. Up to May 2008, a search for the words "Meckel's diverticulum" on Pubmed showed 2,835 articles. However, the emergency surgery as part of the symptomatic Meckel's diverticulum is still deficient in literature. This seems to be so because most of the articles have been in form of case reports or case series, and therefore the management strategies have been highly individualized based on both the patients' condition and on the surgeons' perspective (6).

References

1. **Kuwajerwala NK.** Meckel Diverticulum. Medscape.
2. **Zinner MJ, Schwartz SI, Ellis H.** Maingot's Abdominal operations. 10th ed. New York: McGraw-Hill, Maingot's Abdominal Operations, 1997.
3. **Stone PA, Hofeldt MJ, Lohan JA, Kessel JW, Flaherty SK.** A rare case of massive gastrointestinal hemorrhage caused by Meckel's diverticulum in a 53-year-old man. *W V Med J* 2005; 101: 64–66.
4. **Evers BM.** Small Intestine. In: Sabiston Textbook of Surgery. 17th edition. Edited by Townsend CM. Elsevier; 2004: 1366–1368.
5. **Sagar J, Kumar V, Shah DK.** Meckel's diverticulum: a systematic review. *J R Soc Med.* 2006 October; 99(10): 501–505.
6. **Sharma RK, Jain VK.** Emergency Surgery for Meckel's diverticulum. *World J Emerg Surg* 2008, 3: 27 doi:10.1186/1749-7922-3-27.

Received June 3, 2013.

Accepted January 10, 2014.